

# Impact of Endoscopic Vacuum Therapy with Low Negative Pressure for Esophageal Perforations and Postoperative Anastomotic Esophageal Leaks

Carlo Felix Maria Jung<sup>a</sup> Annegret Müller-Dornieden<sup>b</sup> Jochen Gaedcke<sup>b</sup>  
Steffen Kunsch<sup>a</sup> Mark A. Gromski<sup>c</sup> Lorenz Biggemann<sup>d</sup>  
Ali Seif Amir Hosseini<sup>d</sup> Michael Ghadimi<sup>b</sup> Volker Ellenrieder<sup>a</sup> Edris Wedi<sup>a</sup>

<sup>a</sup>Department of Gastroenterology and Gastrointestinal Oncology, University Medical Center Göttingen, Göttingen, Germany; <sup>b</sup>Department of General-, Visceral- and Pediatric Surgery, University Medical Center Göttingen, Göttingen, Germany; <sup>c</sup>Division of Gastroenterology and Hepatology, Indiana University School of Medicine, Indianapolis, IN, USA; <sup>d</sup>Institute for Diagnostic and Interventional Radiology, University Medical Center Göttingen, Göttingen, Germany

## Keywords

Endoscopic vacuum therapy · Endoscopic negative pressure therapy · Anastomotic leak · Esophageal perforation · Pre-emptive · Esophagectomy esophageal neoplasm · Minimally invasive endoscopic treatment

## Abstract

**Introduction:** Management of esophageal anastomotic leaks (AL) and esophageal perforations (EP) remains difficult and often requires an interdisciplinary treatment modality. For primary endoscopic management, self-expanding metallic stent (SEMS) placement is often considered first-line therapy. Recently, endoscopic vacuum therapy (EVT) has emerged as an alternative or adjunct for management of these conditions. So far, data for EVT in the upper gastrointestinal-tract is restricted to single centre, non-randomized trials. No studies on optimal negative pressure application during EVT exist. The aim of our study is to describe our centre's experience with low negative pressure (LNP) EVT for these indications over the past 5-years. **Patients and Meth-**

**ods:** Between January 2014 and December 2018, 30 patients were endoscopically treated for AL ( $n = 23$ ) or EP ( $n = 7$ ). All patients were primarily treated with EVT and LNP between  $-20$  and  $-50$  mm Hg. Additional endoscopic treatment was added when EVT failed. Procedural and peri-procedural data, as well as clinical outcomes including morbidity and mortality, were analysed. **Results:** Clinical successful endoscopic treatment of EP and AL was achieved in 83.3% ( $n = 25/30$ ), with 73.3% success using EVT alone ( $n = 22/30$ ). Mean treatment duration until leak closure was 16.1 days (range 2–58 days). Additional treatment modalities for complete leak resolution was necessary in 10% ( $n = 3/30$ ), including SEMS placement and fibrin glue injection. Mean hospital stay for patients with EP was shorter with 33.7 days compared to AL with 54.4 days ( $p = 0.08$ ). Estimated preoperative 10-year overall survival (Charlson comorbidity score) was 39.4% in patients with AL and 59.9% in patients with EP ( $p = 0.26$ ). A mean of 5.1 EVT changes (range 1–12) was needed in EP and 3.6 changes (range 1–13) in AL to achieve complete closure, switch to other treatment modality, or reach endoscopic failure ( $p = 0.38$ ). **Conclusion:** LNP EVT enables effec-

tive minimally – invasive endoluminal leak closure from anastomotic esophageal leaks and EP in high-morbid patients. In this study, EVT was combined with other endoscopic treatment options such as SEMS placement or fibrin glue injection in order to achieve leak or perforation closure in the vast majority of patients (83.3%). Low aspiration pressures led to slower but still sufficient clinical results.

© 2020 The Author(s)  
Published by S. Karger AG, Basel

## Introduction

Anastomotic esophageal leaks are treated with different modalities depending on multiple features, including the size and chronicity of leak. Management options are early surgical revision (<72 h after initial operation), endoluminal management or, rarely, cervical esophagostomy. For perforations of the luminal upper gastrointestinal (GI)-tract, endoscopic measures are often attempted initially when mediastinitis is not present and the patient is stable.

The chronicity of leakage, size of the leak and the site of leakage play a crucial role in initial management decisions. Different endoscopic closure techniques may be applied, including the use of through-the-scope clips, over-the-scope-clips, self-expanding metal stent (SEMS), endoscopic suturing and endoscopic vacuum therapy (EVT) [1, 2]. Leakages are reported to occur in 9.5–40% after upper GI surgery [3, 4]. Mortality of anastomotic leak (AL) following surgery is approximately 10% and may decrease to <10% in experienced high-volume centres [1, 5]. For >10 years, EVT has been used with promising results for anastomotic break-down after colon resections [6]. After these encouraging results, it has since been used for leak management in the upper GI tract [7–9].

Randomized controlled trials comparing endoscopic treatment options do not exist in this highly morbid and heterogeneous patient cohort. The available data on EVT are from single-centre retrospective series, which report leakage closure rates by EVT between 70 and 100% [10]. The largest cohort is reported by Bludau et al. [11] with 77 patients. The use of EVT started in Germany, propagated by Wedemeyer and Loske et al. [7, 8, 12, 13]. In the beginning, the EVT sponges had to be manually prepared and assembled by the treating physician. Recently, however, only one readymade sponge kit is commercially available for use in the upper GI (Esosponge Braun B Melsungen, Germany). This product is approved for use

in esophageal perforations (EP) and ALs only and not for pre-emptive EVT.

The aim of this study is to describe the treatment modalities, clinical success rates and clinical outcomes of patients undergoing management of AL or EP with low negative pressure (LNP) vacuum treatment at our centre over a 5-year study period.

## Patients and Methods

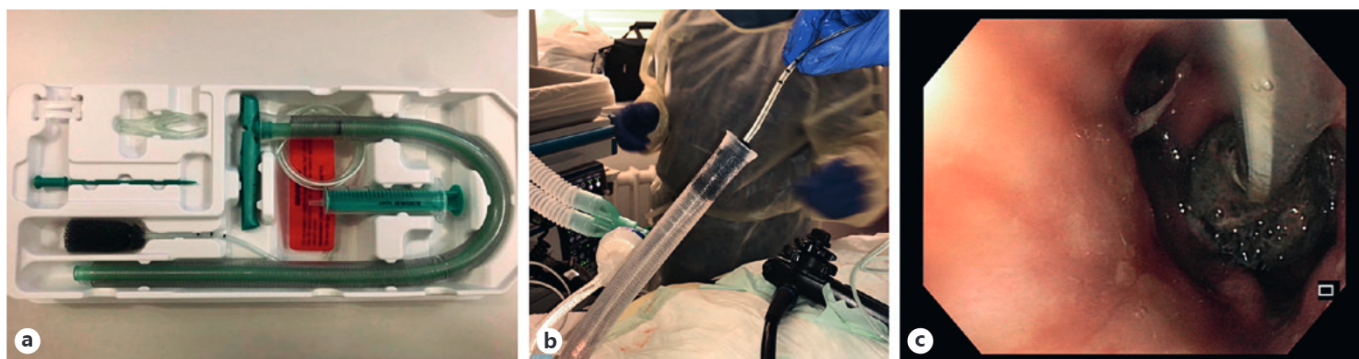
We performed a retrospective analysis of our endoscopic database (WinData E&L Medical Systems GmbH, Erlangen, Germany). The study was approved by our institutional review board at the University Medical Center Göttingen. The study period was January 2014 until December 2018. Patients presenting with post-operative AL after upper GI surgery, EP and patients receiving pre-emptive EVT for anastomosis at risk or intraoperative signs of ischemia were included. We also included patients who initially received surgical revision and developed ALs with the need of EVT later on. Patients who initially received successful surgical revision were excluded from this study.

### *Inclusion Criteria*

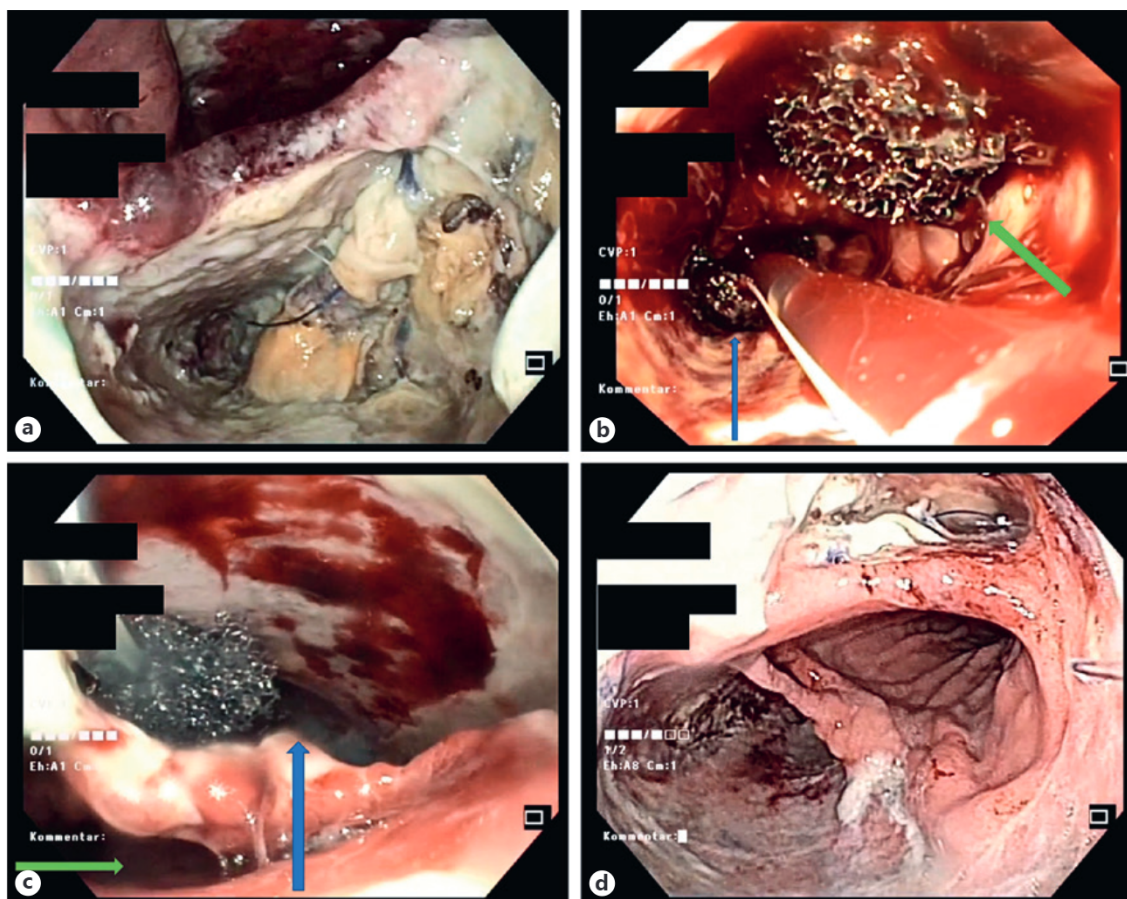
All patients receiving an endoscopic treatment for an AL or EP during the study time period were included. Informed consent for treatment was obtained by every patient or guardian prior to therapy. Eligible endoscopic treatments included a certified negative pressure device for treatment of ALs and perforations, which could be manually modified (Eso-Sponge® – Braun B Melsungen, Germany; size 2: external overtube size 19 mm; Fig. 1a–c), over-the-scope-clips placement (over-the-scope-clip, OVESCO AG, Tübingen, Germany), or Histoacryl fibrin glue (Beriplast P, Combi Set, CSL Behring, Marburg, Germany). Patients treated with self-expanding metal stents (SEMS, Full covered stents Mandel + Rupp NITI-S Fistel-Stent, Erkrath, Germany) were analysed but excluded from this study.

Patient demographic data, clinical data regarding the leak, endoscopic reports and clinical follow-up data were collected and evaluated. Also, time from surgery to diagnosis was evaluated. Delay between diagnosis and EVT placement has retrospectively not been evaluated as most of the diagnosis was made endoscopically and EVT placement was performed right away. In cases where diagnosis was performed by imaging studies, EVT placement was performed on the same day or <24 h afterwards. To compare individual morbidity, the Charlson comorbidity score was calculated prior to leak development, giving a prediction for overall 10-year survival in percentage. Clinical success was defined as closure of initial AL or EP and resolution of purulent secretion by any endoscopic means evaluated during endoscopy. Kuehn et al. [10], Möschler et al. [14] and Donatelli et al. [15] described different EVT and SEMS placement techniques. The EVT placement technique in this study is described below.

EVT was either placed intraluminally or intracavitarily (Fig. 2a–d), the latter one represents a technique that was first described by Loske et al. [13]. The standard recommended EVT-aspiration pressure is generally –125 mm Hg [16]. Clinical evidence of best applied negative pressure, however, is not available yet. In our cohort, we applied negative pressure of –20/–50 mm Hg, in an



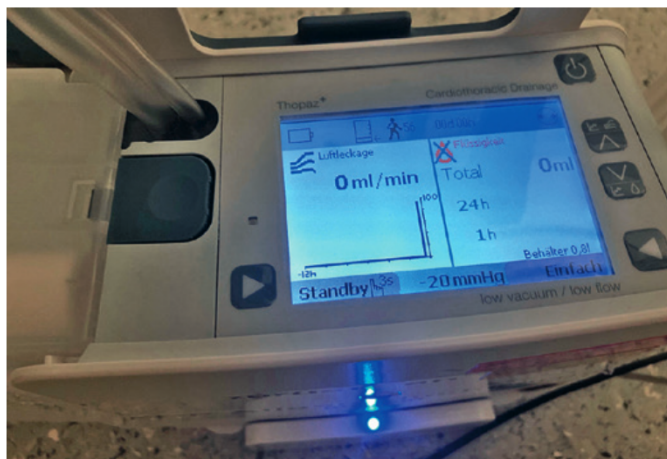
**Fig. 1.** **a** Eso-Sponge<sup>®</sup> by Braun B Melsungen; **(b)** size 2: Eso-Sponge insertion via overtube; **(c)** intraluminal EVT.



**Fig. 2.** **a** Large AL and dehiscence; **(b)** simultaneous intraluminal and intracavitary EVT (blue arrow: intraluminal EVT; green arrow: intracavitary EVT); **(c)** intracavitary EVT (blue arrow: cavity with EVT; green arrow: oesophageal lumen); **(d)** intermediary results after EVT.

effort to protect anatomical structures in proximity to the cavity. This decision for LNP was taken interdisciplinary with the surgeons. We preferred LNP in intrathoracic cavities to avoid local tissue damage and our clinical experience showed that LNP was sufficient for local debridement.

Statistical analyses and group comparison were performed using unpaired *t* tests with Prism 8 statistical software (GraphPad Software, San Diego, CA, USA). A *p* value of <0.05 was considered statistically significant.



**Fig. 3.** Medela Thopaz<sup>+</sup> digital chest drainage and monitoring system.

#### *Peri-Procedural Management during EVT Therapy*

Patients treated with EVT received nasogastric/nasojejunal tube insertion for direct enteral nutrition, when possible. Otherwise, total parenteral nutrition was provided for nutritional support. Additionally, proton pump inhibitors IV (e.g., 40 mg pantoprazole) were administered during the first 2 weeks in order to minimize gastric acid secretion. As soon as leakage or perforation was confirmed, an antibiotic and antifungal regimen consisting of Vancomycin (1 g intravenous [i.v.] 2 times a day, then dose adaptation according to therapeutic serum levels), Meropenem (1 g i.v. 3×/day) and Caspofungin (initial dose 70 mg, then 50 mg once a day i.v.) was administered.

#### *EVT Procedure*

EVT can be either applied into a cavity connected to the AL or intraluminally (in the case of a free perforation). In general, prepared EVT kits consist of a polyurethane sponge, connected to a tube over which negative pressure can be applied via an external suction pump (e.g., Medela Thopaz, Medela Medizintechnik, GmbH & Co., Handels KG, Germany), similar to drainages in thoracic surgery (Fig. 3). First, wound cavities beyond the leak are carefully examined endoscopically. In this first step, pus-filled cavities are lavaged carefully and the endoscopist can obtain an overview of the local anatomical structures. During the time period of this study, the index endoscopy was always performed in the presence of a general surgeon, and treatment decisions were created in multidisciplinary fashion. When deploying the EVT, an overtube is placed trans-orally into the cavity or intraluminally. Then the Eso-Sponge<sup>®</sup> was inserted into the oesophagus via the overtube. The exact position is finally adjusted under endoscopic view using a standard grasper. Before connecting the tube to the external suction pump, the drainage tube is externalized transnasally and fixed to the nose using standard medical tape. Initially, the drain is placed like an esophagogastral tube and connected to the rest of the sponge device.

Sponge change is repeated every 3–4 days to minimize the risk of severe bleeding and sponge adhesion to the oesophagus or the wound cavity. Additionally, wound healing or deterioration could

be controlled this way. During changes, the sponge can be pulled out after setting negative pressure to zero. Then, endoscopic re-application is performed.

In one case with complete anastomotic dehiscence and 2 cavities, 2 sponges were placed at a time temporarily, each into one of the cavities. After 2 weeks, the EVT treatment was continued with 1 sponge intraluminally.

## **Results**

### *Overall Results*

In total, 23 patients with postoperative leakages (6 women, 17 men; mean age women 67.2 years/men 64.5 years) and 7 patients with EPs (4 women, 3 men; mean age women 68.7 years/men 62.3 years) were studied in our cohort. All patients were primarily treated with EVT. General patient characteristics are displayed in Table 1 and special patient characteristics per group are displayed in Table 2 for AL and in Table 3 for EP. During the study period, a total of 272 patients received Ivor Lewis esophagectomies at our surgical department. Of these 272 patients, 15 patients developed postoperative AL with attempted endoscopic treatment (5.5%).

Clinical success by all endoscopic interventions and methods together was 83.3% ( $n = 25/30$ ). Solo EVT treatment was successful in 73.3% in AL and EP ( $n = 22/30$ ). Leaks requiring a combination of different endoscopic devices were present in 3 patients. Here, leak closure was ultimately achieved in all patients.

Mean duration of endoscopic treatment leading to successful closure of AL and EP (all endoscopic treatments included,  $n = 25/30$ ) was 18 days (range 2–58 days) with a mean number of 4.2 EVT changes per patient (range 1–13).

For patients with successful EVT treatment alone in AL and EP, the mean duration for closure in all patients was 16.1 days.

### *Subgroup Results: AL versus EP*

#### *AL Group*

In the AL group ( $n = 23$ ), overall treatment success was 87.0% ( $n = 20/23$ ) and solo EVT treatment success was 78.3% ( $n = 18/23$ ). Mean treatment duration for leak closure was 15.7 days for all treatments and 13.9 days when treated only with EVT. Mean hospital stay in AL was 54.4 days. Two patients were hospitalized for >120 days in the intensive care unit. Diagnosis of AL was made between the range of POD 0–30 (mean 8.5 days).

In total, a mean of 3.4 EVT changes (range 1–13×;  $n = 18/23$ ) for achieving wound healing were applied. Two

**Table 1.** General patient characteristics

General patient characteristics	Overall patients	AL	Perforations	<i>p</i> value
Indication for EVT, <i>n</i>				
Total number of patients	30	23	7	
Male	20	17	3	
Female	10	6	4	
Age, years, mean (SD)				
Male		64.5 (11.6)	62.3 (8.1)	
Female		67.2 (6.5)	68.7 (6.9)	
Charlson Morbidity Score		4.9 (39.4)	3.9 (59.9)	0.26
Cause for surgery, <i>n</i>				
Malignancy		23		
Adenocarcinoma		17		
Squamous cell carcinoma		5		
Neuroendocrine carcinoma		1		
Neoadjuvant therapy, <i>n</i>				
Total		18		
Chemotherapy only		13		
Radiochemotherapy		5		
Not specified		5		
Diagnosis at day, days		8.50	Immediately	
Length of hospital stay, days		54.4	33.7	0.08
Mortality, <i>n</i> (%)	2/30 (6.67)	1	1	

AL, anastomotic leak; EVT, endoscopic vacuum therapy.

patients received additional endoscopic treatments when primary treatment with EVT did not provide definitive leak closure ( $n = 1$  oesophageal SEMS placement,  $n = 1$  fibrin glue injection). The mean estimated 10-year overall survival in this patient cohort was 39.4% (Charlson comorbidity score).

In  $n = 18/23$  patients (78.2%), oncologic upper GI resection was performed after perioperative radio-chemotherapy. Prior to EVT, 20% of patients with AL ( $n = 6/30$ ) received surgical revision in between the day of operation and POD 12 (mean 4.3 days). All surgically revised patients showed no healing and were therefore converted to EVT treatment. Five patients in AL group received prophylactic EVT during operative or postoperative course, where the anastomosis was considered in danger of dehiscence. Two out of five patients developed frank leakage at the time of therapy and were treated over a longer course. Three patients received 1 course of EVT, and anastomosis healed normally.

#### EP Group

Overall treatment success in this group was 71.4% ( $n = 5/7$  patients). Success of solo primary EVT was 57.1% ( $n = 4/7$ ). Mean treatment duration for perforation closure was 27 days for all treatments and 25.5 days when treated

only with EVT. Mean hospital stay was 33.7 days. The hospital stay was not significantly different between the groups (54.4 AL vs. 33.7 days EP;  $p = 0.08$ ). A mean of 6.4 EVT changes (range 1–12 $\times$ ) for perforation closure were necessary in this group. Estimated 10-year overall survival calculated by the Charlson comorbidity score was 59.9%. No significant difference was found concerning morbidity between AL and EP (AL 39.4 vs. EP 59.9%,  $p = 0.26$ ).

All patients ( $n = 7$ ) received primary EVT. In 1 patient, SEMS placement was necessary to achieve complete wound healing. In 1 patient, palliative EVT was realized for iatrogenic perforation after dilation for stenotic oesophageal cancer. Treatment was stopped after 1 session of EVT with no treatment effect seen. The patient was transferred to palliative care ward afterwards. In a second patient, no defect closure after Boerhaave associated perforation was seen. Here, distal esophageal and gastric resection with cervical esophagostomy was necessary.

#### Intracavitary versus Intraluminal Treatment

General technical characteristics are shown in Table 4. Primary intracavitary EVT was initiated in  $n = 6/30$  patients ( $n = 3/23$  patients AL and in  $n = 3/7$  patients

**Table 2.** Detailed patient and treatment characteristics for ALs

Gender	Operation	Anastomosis	Tumor	Age at intervention	Insufficiency height, cm	Diagnosis at POD	Endoscopic intervention	EVT changes/ other treatment	Intracavitary (C)/ intraluminary (L) radio/RCT	Prior radio/RCT	Success	Leak size
Female	Ivory Lewis	Esophagogastrostomy	AEG II	66	21	30	EVT	4	C; later L	Yes	Yes	1–2 cm
Male	Ivory Lewis	Esophagogastrostomy	SCC	61	20	12	EVT/stent	6 + stent I	L	Yes	Yes + add	>2 cm
Male	Ivory Lewis	Esophagogastrostomy	AEG I	57	25	7	EVT	13	L	Yes	Yes	>2 cm
Female	Ivory Lewis	Esophagogastrostomy	NEC	71	19	4	EVT	2	L	No	Yes	<5 mm
Female	Ivory Lewis	Esophagogastrostomy	SCC	73	25	2	EVT	4	L	Yes	Yes	1–2 cm
Female	Ivory Lewis	Esophagogastrostomy	SCC	67	Anastomosis	30	EVT	3	L	Yes	Yes	<5 mm
Male	Ivory Lewis	Esophagogastrostomy	AEG I	65	26	9	EVT	8	L	Yes	Yes	1–2 cm
Male	Ivory Lewis	Esophagogastrostomy	AEG II	51	25	8	EVT	9	L	Yes	Yes	0.5–1 cm
Male	Ivory Lewis	Esophagogastrostomy	AEG I	59	Anastomosis	13	EVT	3	L	Yes	Yes	<5 mm
Male	Ivory Lewis	Esophagogastrostomy	AEG I	83	33	0	EVT	1	L	Yes	Yes	×
Male	Ivory Lewis	Esophagogastrostomy	SCC	76	25	12	EVT	1	L	Yes	Yes	×
Male	Ivory Lewis	Esophagogastrostomy	AEG I	56	27	2	EVT	6	L	Yes	No	0.5–1 cm
Male	Ivory Lewis	Esophagogastrostomy	AEG II	78	25	6	EVT	1	L	No	Yes	<5 mm
Female	Ivory Lewis	Esophagogastrostomy	SCC	55	25	13	EVT	1	L	Yes	Yes	1–2 cm
Male	Ivory Lewis	Esophagogastrostomy	AEG I	53	26	1	EVT	2	L	Yes	Yes	<5 mm
Male	Gastrectomy	Esophagojejunostomy	AEG II	61	35	0	EVT	2	L	Yes	Yes	0.5–1 cm
Male	Gastrectomy	Esophagojejunostomy	AEG III	66	35	16	EVT	1	L	Yes	Yes	<5 mm
Male	Gastrectomy and distal esophagectomy	Esophagojejunostomy	AEG II	49	39	1	EVT	3	L	Yes	Yes	<5 mm
Female	Gastrectomy	Esophagojejunostomy	AEG II	71	38	6	EVT + fibrine	4 + fibrine	L	No	Yes + add	1–2 cm
Male	Gastrectomy	Esophagojejunostomy	AEG III	79	39	24	EVT	2	C; later L	Yes	No	1–2 cm
Male	Gastrectomy	Esophagojejunostomy	AEG II	52	40	1	EVT	3	L	Yes	Yes	<5 mm
Male	Gastrectomy	Esophagojejunostomy	Gastric adenocarcinoma	84	40	14	EVT	1	C; later L	No	Yes	<5 mm
Male	Gastrectomy	Esophagojejunostomy	AEG I	67	37	0	EVT	3	L	No	No	>2 cm

AL, anastomotic leak; AEG, adenocarcinoma of the esophagogastric junction; EVT, endoscopic vacuum therapy; NEC, neuroendocrine carcinoma; SCC, squamous cell carcinoma; POD, post-operative day.

**Table 3.** Detailed patient characteristics for EPs

Gender	Indication	Tumor	Age at intervention	Perforation height, cm	Endoscopic intervention	EVT changes/ other treatment	intracavitary (C)/ intraluminal (L)	Prior radio/RCT	Success	Leak size
Female	Transesophageal echo	No	63	16	EVT	12	C; later L		Yes	1–2 cm
Female	Endoscopic dilation	No	78	33	EVT	2	L		Yes	1–2 cm
Female	Postoperative torquation	No	64	35	EVT	6	L		Yes	<5 mm
Female	Gastroscopy	SCC	70	35	EVT + stent	3/1 stent	C; later L	Radiation	Yes	>2 cm
Male	Boerhaave	No	68	35	EVT	3	L		No	<5 mm
Male	Ischemia	No	66	32	EVT	9	L		Yes	>2 cm
Male	Endoscopic dilation	AEG II	53	35	EVT	1	C; later L		No	>2 cm

EP, esophageal perforation; SCC, squamous cell carcinoma; EVT, Endoscopic Vacuum Therapy.

**Table 4.** Technical characteristics for AL and EP

	Overall patients	Anastomotic insufficiency	Perforations
Number of EVT changes, mean	4.2	3.4	6.4
First line EVT	30	23	7
Intracavitary EVT	6	3	3
Intraluminal EVT	24	20	4
Additional SEMS	2	1	1
Additional fibrine glue	1	1	
Prior surgical revision		6	0
Esophagostomy/esophagectomy		2 (esophagostomy)	1 (esophagectomy + stomy)

AL, anastomotic leaks; EP, esophageal perforations; EVT, endoscopic vacuum therapy; SEMS, self-expanding metal stent.

EP) before switching to intraluminal treatment. Intracavitary treatment with LNP showed in this subgroup significant cavity size reduction in only 2 out of 6 patients. In 4 out of 6 patients, intracavitary EVT with LNP was insufficient to complete leak closure. Therefore, additional endoscopic treatment had to be applied (2× SEMS). One patient proceeded to esophageal cervicostomy and 1 patient died before further endoscopic treatment.

Primary intraluminal treatment was initiated in 24 out of 30 patients ( $n = 20/23$  patients in AL and  $n = 4/7$  patients in EP), accordingly. In 4 out of 24 intraluminal treatment did not lead to leak closure. Two patients received cervical anastomosis, one additional fibrin glue injection before leak closure and 1 patient died during treatment.

### Complication, Technique Failure and Mortality

With LNP almost no mucosal erosion patterns after EVT were seen. Information of fluid in the Medela suction container was retrospectively not obtained. Bleeding rate after EVT was 7% ( $n = 2/30$ ), which might also speak for few mucosal attachment. Bleeding could be managed endoscopically. No major bleeding was documented.

In cases where a feeding tube was placed besides the sponge, no adverse events occurred.

A total of 3 patients received cervical esophagostomy after failure of endoscopic therapy (2 AL, 1 EP, EVT duration: 5, 9 and 17 days). Clinical failure was defined as continuous purulent secretion, persistence of leak without healing tendency and progression of leak during endoscopic treatment.

Two patients out of 30 died during the immediate clinical follow-up (mortality 6.7% over all groups). Death was not directly related to endoscopic treatment but due to septic complications, multi-organ failure or progressive oncologic disease.

#### *AL Group*

In 3 patients, endoscopic treatment failed. In total, 1 patient died due to reasons not related to endoscopic treatment ( $n = 1$ : multi-organ failure after mixed cardiogenic and septic shock). In this patient, leakage closure could not be achieved.

EVT was well tolerated by all patients except one who externalized his EVT within the first day of EVT treatment. Two patients received cervical esophagostomy as endoscopic therapy did not achieve leak closure.

#### *EP Group*

In 2 patients endoscopic treatment failed. In 1 patient, progressive ischemic esophageal and gastric necrosis was seen, leading to partial esophagectomy and total gastrectomy.

In another patient, advanced esophageal cancer with stenosis was present. The patient was transferred to our hospital due to iatrogenic perforation after esophageal balloon dilation. EVT did not lead to immediate wound healing. The patient was transferred to the palliative ward.

### **Follow-Up**

Clinical follow-up data (>3 months) was available for 15 out of 30 patients (AL 13/23 patients and EP 2/7 patients). Mean follow-up time was 11.8 months in AL and 10 months in EP (range 3–30 months). Reasons for missed follow-up were: in house mortality, loss to follow-up or recently finished endoscopic treatment <3 months. Patients in AL developed anastomotic strictures in 3 cases and a colonic-tracheal fistula in 1 case after colon interposition. Ten patients remained without stenosis or cancer recurrence. In the EP group, 1 patient developed stenosis due to initially non-diagnosed squamous cell carcinoma. The second patient remained without stenosis.

### **Discussion**

Within the past few years, EVT has been implemented as a treatment option for upper GI-tract luminal defects besides SEMS placement [7, 8]. Since then, several case

series have been published, reporting treatment success for EVT in AL and EP in up to 90–100% [10]. Nevertheless, there is still a lack of research in this field and several clinical questions concerning EVT remain unanswered. The biggest study cohort analysed so far was published by Laukoetter et al. [17] with 52 patients and the cohort of Bludau et al. [11] with 77 patients. Although EVT has been showing promising results, its use is not yet included in European Society of Gastrointestinal Endoscopy or other endoscopic guidelines currently.

In our study, overall treatment success was 83.3% for all treatment options and success for EVT alone in all cohorts was 73.3%. Concerning EVT success, our results are slightly inferior to larger EVT studies by Laukoetter and Hwang et al. [17, 18] but similar to Bludau et al. [10, 11] (see also Table 5). A possible bias might be the extent of anastomotic insufficiency/leak or in fact less negative pressure. In our cohort, at least 2 patients showed complete circular AL with additional fistulas, necessitating repetitive EVT [19]. Perhaps, these patients would be considered not fit for EVT and undergo final esophagostomy in other cohorts. A further reason could be delayed diagnosis of AL in the studied cohort (mean 8.6 days, range 0–30 days).

Another point of discussion is the use of preformed commercially available EVT kits in this study. These highly individual conditions may often require creative and individually prepared sponges. In some cases, preformed kits were manually adjusted before use in our cohort. Nevertheless, individual sponge adjustment was probably less performed in our cohort when compared to other studies.

During the last years, EVT showed better results than SEMS placement for leakages and perforations. In Laukoetter et al. [17], patients primarily treated with SEMS had to be switched more often to EVT to achieve oesophageal healing. EVT success rate was 93.3% in comparison to 63.3% (SEMS) respectively [20]. In a recent meta-analysis, Rausa et al. [21] showed that EVT in contrast to SEMS treatment in oesophageal leaks has a lower major complication rate, needs less treatment duration and shows lower in house mortality.

Whereas EVT in general is an acknowledged method, no human studies or experiences exist so far concerning choosing the best applied negative pressure. In general, –125 mm Hg negative pressure are applied via KCI (Kinetic Concepts Inc., San Antonio, TX, USA) or other pumps able generating this negative pressure as recommend by the companies.

In our cohort, negative pressure used, ranged between –20 and –50 mm Hg, which is lower than in any other study. Nevertheless, all patients treated with –20 mm Hg



**Table 5.** Comparison of EVT cohorts

References	Journal	Patients, <i>n</i>	Overall success rate, <i>n</i> (%)	Success rates for AL, <i>n</i> (%)	Success rate for EP, <i>n</i> (%)	Duration of therapy, days, median	Hospital mortality, %	Additional endoscopic treatment
Bludau et al. [11]	Surg Endosc 2018	77	60/77 (77.9)	46/59 (77.9)	13/18 (72.2)	11	12.90	Yes
Laukoetter et al. [17]	Surg Endosc 2017	52	49/52 (94.2)	36/39 (92.3)	13/13 (100)	22	9.60	Yes
Smallwood et al. [26]	Surg Endosc 2016	6	6/6 (100)	5/5 (100)	–	36	0	Yes
Kuehn et al. [10]	Surg Endosc 2017	21	19/21 (90.5)	9/11 (82)	10/10 (100)	15	5	No
Schorsch et al. [22]	Surg Endosc 2013	35	32/35 (91)	20/21 (95)	7/7 (100)	11	5.70	–
Brangewitz et al. [27]	Endoscopy 2013	32	27/32 (84.4)	–	–	23 EVT/ 33 SEMS	15.6 EVT/ 25.6 SEMS	No
Jung et al. (this study)	Digestion 2020	30	25/30 (83.3)	20/23 (86.96)	5/7 (71.43)	11 (mean 18)	6.67	Yes

EVT, endoscopic vacuum therapy; AL, anastomotic leak; EP, esophageal perforations; SEMS, self-expanding metal stent.

up to –50 mm Hg negative pressure application showed sufficient healing. After LNP EVT in our cohort, we rarely experienced erosion patterns, which are usually present in high LNP EVT. It is possible that the way of action of LNP is more fluid aspiration (including gastric acid fluid and biliary reflux after Ivor-Lewis resection) than active wound healing. This may show the importance of these fluids impairing wound healing. On the other hand, this way of action might explain why LNP is leading to slower healing times. Time of EVT application until leak closure was not different compared to most of the studies [10]. But when compared to the cohort of Bludau et al. [11] and also Schorsch et al. [22], treatment with LNP in our cohort was longer and led to less treatment success (mean 18 days Jung et al. (this study) vs. 11.0 days Bludau et al. [11]/Schorsch et al. [22]; mean EVT changes 4.2 Jung et al. (this study) vs. 2.75 Bludau et al. [11]).

An additional new aspect of our study is the use of the Medela (Thopaz) pump for generating moderate negative pressure. Normally the Medela pump is used in thoracic drains. LNP build-up can be reached slowly using this pump. Nevertheless, as leak closure in our cohort took more time, slow build up pressure has to be discussed whether it is suitable for EVT or not.

An advantage is the monitoring, where an hourly fluid quantity is displayed. In case of haemorrhagic fluid secre-

tions, actions can be taken according to displayed information. In our experience, the Medela Thopaz drainage system was well combined with the Eso-Sponge kit used in this study.

It has to be emphasised, that the concept of applying –125 mm Hg negative pressure was transferred from early skin vacuum therapy studies from Morykwas et al. [23, 24]. The authors found, that maximum increase of wound blood flow was reached at a negative pressure of –125 mm Hg leading to improved oxygenation, nutrient delivery to the wound bed and faster tissue granulation. Nevertheless, these experiments were performed on open skin wounds and not on intestinal structures with delicate surrounding tissues such as visceral pleura or vascular structures. We are convinced that lower pressure secures surrounding tissue and prevents further fistula formation or bleeding. In our cohort, patients receiving intracavitary placement of EVT, had no reported fistula formation during the initial clinical course. Interestingly, fistula formation has not been described in large EVT cohorts even when applying –125 mm Hg negative pressure. In contrast to this, bleeding associated with EVT is a known complication, reported also by Laukoetter et al. [17].

In total, our clinical experience confirms the suspicion that LNP might be also sufficient for local wound debridement and healing. Nevertheless, it cannot be ruled

out that LNP leads to slower wound closure and less treatment success when compared to EVT with  $-125$  mm Hg. In our opinion, draining crucial fluids is one part of the necessary treatment, but inducing mucosal healing with high negative pressure applied to the mucosa might be important as well. Probably the latter point is of interest for faster and more sufficient mucosal healing when compared to LNP. Future research in this field should elucidate this interesting and clinically important question of EVT pressure. In our opinion a final statement concerning strength of negative pressure can't be given yet, due to low evidence degree of existing clinical data.

A further important issue in EVT is the positioning of the sponge. Intracavitary EVT was first described by Loske et al. [13], reporting high closure rates of 100% after a mean of 4 EVT changes using  $-125$  mm Hg negative pressure in their cohort of EPs. Interestingly in our cohort, intracavitary treatment was not as effective as foreseen. Only 2/6 patients showed leak/perforation closure after intracavitary EVT and 2 patients needed additive endoscopic treatment, 1 patient received esophageal cervicostomy and 1 patient died. On the other hand, we treated 24 patients intraluminally with a success rate of 83.3%. LNP may had an important role in less efficient healing in intracavitary treatment. Probably, with LNP, the cavities were not efficiently closed, therefore fluids could still reach the cavity and wound healing was slowed down.

The mortality rate in our study was 6.7% and therefore similar to the ones reported in the cohorts of Laukoetter et al. [17] (9.6%) and Bludau et al. [11] (12.9%). Interestingly, in 2017 and 2018, no patients died due to ALs in our institution and only 3/22 patients (13.6%) were finally converted to esophagostomy. We have observed a learning curve with the EVT, which might play a crucial role for the clinical outcome. Hospital stay was significantly longer in patients with AL in comparison to EP, perhaps due to more severe comorbidities, including oncologic disease.

EVT failure was seen in 26.7% ( $n = 8/30$ ) of all patients in our cohort. Reasons for EVT failure were insufficient anastomotic perfusion, for which no new granular tissue was able to spread. Furthermore sponge positioning, negative pressure, prior radiochemotherapy, comorbidities and the experience of the endoscopic centre with EVT might play a crucial role for the outcome. Immediate adverse events due to EVT were rarely seen in our cohort. Two out of 30 patients presented minor bleeding directly after sponge removal and could be treated endoscopically. Complications rates were comparable with published data [10, 17].

From the endoscopists point of view EVT comes along with certain important advantages. First, wound healing is observed in a repetitive manner. Second, EVT will actively aspirate necrotic/purulent tissue, promote wound healing and collapse wound cavities. It is the first endoscopic tool which allows active local wound debridement and healing. Disadvantages are treatment costs [25], repeated endoscopies with multiple sedations and difficulties concerning re-nutrition as long as a nasogastric tube is not placed at the same time.

## Conclusion

LNP EVT shows comparable results to  $-125$  mm Hg EVT for upper GI leakages and perforations. Major way of action might be aspiration of biliary, gastric and purulent fluids. Intracavitary EVT treatment was not as efficient as intraluminal EVT in our cohort with LNP. Limitations of this study include retrospective nature, relatively small size, single centre design and lack of clinical follow-up in all patients.

We recommend that treatment of leakages and perforations should always be discussed interdisciplinary and be adapted according to clinical success and wound healing or failure. Large, prospective and comparative studies are needed to better understand the role of LNP EVT compared to other treatment strategies.

## Acknowledgements

We sincerely thank our study nurse Ms. Kathrin Salzmann for data recruitment and analysis.

## Statement of Ethics

The study complies with the principles of the Declaration of Helsinki. The study protocol was approved by the Ethics Committee of the University Medical Centre of Göttingen (approval number 6/4/19).

## Disclosure Statement

All authors have no conflict of interest or financial ties to disclose.

## Funding Sources

No funding was received for this study.

## Author Contributions

C.F.M.J. and E.W. were responsible for conception and design of the study, acquisition, analysis, interpretation of data and writing the manuscript. A.M.-D., S.K., and J.G. were responsible for

acquisition of data and critically revising the manuscript. M. G. analyzed the research quality and revised the manuscript. V.E., M.G., L.B., and A.S.A.H. were responsible for critically revising the submitted work including important intellectual content. All authors read and approved the final manuscript.

## References

- 1 Paspatis GA, Dumonceau JM, Barthet M, Meisner S, Repici A, Saunders BP, et al. Diagnosis and management of iatrogenic endoscopic perforations: European Society of Gastrointestinal Endoscopy (ESGE) Position Statement. *Endoscopy*. 2014 Aug;46(8):693–711.
- 2 Rodrigues-Pinto E, Repici A, Donatelli G, Macedo G, Deviere J, Van Hooft JE, et al. 178 International multicenter expert survey on endoscopic treatment of upper gastrointestinal anastomotic leaks. *Gastrointest Endosc*. 2019;89(6):AB59–60.
- 3 Hummel R, Bausch D. Anastomotic Leakage after Upper Gastrointestinal Surgery: surgical Treatment. *Visc Med*. 2017 Jun;33(3):207–11.
- 4 Cooke DT, Lin GC, Lau CL, Zhang L, Si MS, Lee J, et al. Analysis of cervical esophagogastric anastomotic leaks after transhiatal esophagectomy: risk factors, presentation, and detection. *Ann Thorac Surg*. 2009 Jul;88(1):177–84.
- 5 Keeling WB, Miller DL, Lam GT, Kilgo P, Miller JL, Mansour KA, et al. Low mortality after treatment for esophageal perforation: a single-center experience. *Ann Thorac Surg*. 2010 Nov;90(5):1669–73; discussion 1673.
- 6 Weidenhagen R, Gruetzner KU, Wiecken T, Spelsberg F, Jauch KW. Endoscopic vacuum-assisted closure of anastomotic leakage following anterior resection of the rectum: a new method. *Surg Endosc*. 2008 Aug;22(8):1818–25.
- 7 Wedemeyer J, Schneider A, Manns MP, Jackobs S. Endoscopic vacuum-assisted closure of upper intestinal anastomotic leaks. *Gastrointest Endosc*. 2008 Apr;67(4):708–11.
- 8 Loske G, Müller C. [Vacuum therapy of an esophageal anastomotic leakage—a case report]. *Zentralbl Chir*. 2009 Jun;134(3):267–70.
- 9 Loske G, Müller C. Endoscopic vacuum-assisted closure of upper intestinal anastomotic leaks. *Gastrointest Endosc*. 2009 Mar;69(3 Pt 1):601–2.
- 10 Kuehn F, Loske G, Schiffmann L, Gock M, Klar E. Endoscopic vacuum therapy for various defects of the upper gastrointestinal tract. *Surg Endosc*. 2017 Sep;31(9):3449–58.
- 11 Bludau M, Fuchs HF, Herbold T, Maus MK, Alakus H, Popp F, et al. Results of endoscopic vacuum-assisted closure device for treatment of upper GI leaks. *Surg Endosc*. 2018 Apr;32(4):1906–14.
- 12 Loske G, Schorsch T, Müller C. Endoscopic vacuum sponge therapy for esophageal defects. *Surg Endosc*. 2010 Oct;24(10):2531–5.
- 13 Loske G, Schorsch T, Müller C. Intraluminal and intracavitary vacuum therapy for esophageal leakage: a new endoscopic minimally invasive approach. *Endoscopy*. 2011 Jun;43(6):540–4.
- 14 Moschler O, Nies C, Mueller MK. Endoscopic vacuum therapy for esophageal perforations and leakages. *Endosc Int Open* 2015;3:E554–8.
- 15 Loske G, Müller CT. Tips and tricks for endoscopic negative pressure therapy. *Chirurg*. 2019 Jan;90(Suppl 1):7–14.
- 16 Argenta LC, Morykwas MJ. Vacuum-assisted closure: a new method for wound control and treatment: clinical experience. *Ann Plast Surg*. 1997 Jun;38(6):563–76.
- 17 Laukoetter MG, Mennigen R, Neumann PA, Dhayat S, Horst G, Palmes D, et al. Successful closure of defects in the upper gastrointestinal tract by endoscopic vacuum therapy (EVT): a prospective cohort study. *Surg Endosc*. 2017 Jun;31(6):2687–96.
- 18 Hwang JJ, Jeong YS, Park YS, Yoon H, Shin CM, Kim N, et al. Comparison of Endoscopic Vacuum Therapy and Endoscopic Stent Implantation With Self-Expandable Metal Stent in Treating Postsurgical Gastroesophageal Leakage. *Medicine (Baltimore)*. 2016 Apr;95(16):e3416.
- 19 Wedi E, Schüler P, Kunsch S, Ghadimi BM, Seif Amir Hosseini A, Ellenrieder V, et al. Individual endoscopic management of anastomotic insufficiency after esophagectomy for esophageal squamous cell carcinoma and creation of a neostomach. *Endoscopy*. 2018 Mar;50(3):E69–71.
- 20 Mennigen R, Harting C, Lindner K, Vowinkel T, Rijcken E, Palmes D, et al. Comparison of Endoscopic Vacuum Therapy Versus Stent for Anastomotic Leak After Esophagectomy. *J Gastrointest Surg*. 2015 Jul;19(7):1229–35.
- 21 Rausa E, Asti E, Aiolfi A, Bianco F, Bonitta G, Bonavina L. Comparison of endoscopic vacuum therapy versus endoscopic stenting for esophageal leaks: systematic review and meta-analysis. *Dis Esophagus*. 2018 Nov;31(11):31.
- 22 Schorsch T, Müller C, Loske G. Endoscopic vacuum therapy of anastomotic leakage and iatrogenic perforation in the esophagus. *Surg Endosc*. 2013 Jun;27(6):2040–5.
- 23 Morykwas MJ, Argenta LC, Shelton-Brown EI, McGuirt W. Vacuum-assisted closure: a new method for wound control and treatment: animal studies and basic foundation. *Ann Plast Surg*. 1997 Jun;38(6):553–62.
- 24 Argenta LC, Morykwas MJ. Vacuum-assisted closure: a new method for wound control and treatment: clinical experience. *Ann Plast Surg*. 1997 Jun;38(6):563–76; discussion 577.
- 25 Ward MA, Hassan T, Burdick JS, Leeds SG. Endoscopic vacuum assisted wound closure (EVAC) device to treat esophageal and gastric leaks: assessing time to proficiency and cost. *Surg Endosc*. 2019 Dec;33(12):3970–5.
- 26 Smallwood NR, Fleshman JW, Leeds SG, Burdick JS. The use of endoluminal vacuum (E-Vac) therapy in the management of upper gastrointestinal leaks and perforations. *Surg Endosc*. 2016 Jun;30(6):2473–80.
- 27 Brangewitz M, Voigtlander T, Helfritz FA, Lankisch TO, Winkler M, Klempnauer J, et al. Endoscopic closure of esophageal intrathoracic leaks: stent versus endoscopic vacuum-assisted closure, a retrospective analysis. *Endoscopy*. 2013 Jun;45(6):433–8.