

## Original Investigation

# Intraluminal Negative Pressure Wound Therapy for Optimizing Pharyngeal Reconstruction

Scott A. Asher, MD; Hilliary N. White, MD; Elisa A. Illing, MD; William R. Carroll, MD; J. Scott Magnuson, MD; Eben L. Rosenthal, MD

**IMPORTANCE** Pharyngocutaneous fistula formation after pharyngeal reconstruction is one of the most common and challenging problems to manage. Despite many advances in management, the published success rates indicate a role for any adjuvant therapy that could potentially decrease this complication.

**OBJECTIVE** To describe the use of intraluminal negative pressure dressings (NPDs) in pharyngeal reconstruction.

**DESIGN, SETTING, AND PARTICIPANTS** Retrospective case series at a tertiary care academic hospital. Twelve laryngectomy patients underwent pharyngeal reconstruction augmented by placement of an intrapharyngeal NPD in combination with the introduction of vascularized tissue from August 2011 to May 2012. All patients had potential risk factors for compromised wound healing defined as previous radiation therapy, hypothyroidism, diabetes mellitus, compromised nutrition, or established pharyngocutaneous fistula.

**INTERVENTIONS** An NPD was placed in an intraluminal position spanning the length of the pharyngeal defect as part of the reconstructive procedure. The negative pressure sponge was attached to a standard nasogastric tube to which negative pressure was applied. External closure of the pharynx was then achieved with regional or free tissue transfer.

**MAIN OUTCOMES AND MEASURES** Pharyngeal closure rates, timing until return to oral diet, identification of wound healing risk factors, and adverse events related to use of the device.

**RESULTS** Eleven of 12 patients (92%) achieved pharyngeal closure with reconstruction using negative pressure wound therapy. All patients had at least 1 potential risk factor for compromised wound healing, with 11 of 12 (92%) having 2 or more. Seven patients had an established pharyngocutaneous fistula, and 5 patients underwent primary reconstruction after laryngopharyngectomy. In 6 of these 7 patients undergoing fistula repair, pharyngeal closure was achieved, and they resumed an oral diet at 1 week postoperatively. The other had successful leak repair initially, but 1 week later developed a separate area of wound breakdown and a second fistula. All 5 patients in whom an intraluminal NPD was placed at the time of initial vascularized tissue reconstruction were able to resume an oral diet by 3 weeks postoperatively, with 3 of them eating by mouth at 1 week postoperatively. No serious adverse events could be attributed to the use of intraluminal NPDs.

**CONCLUSIONS AND RELEVANCE** Intraluminal negative pressure wound therapy is feasible and safe. Future research should be conducted to determine its potential in optimizing pharyngeal reconstruction in high-risk patients.

*JAMA Otolaryngol Head Neck Surg.* 2014;140(2):143-149. doi:10.1001/jamaoto.2013.6143  
Published online December 26, 2013.

**Author Affiliations:** Division of Otolaryngology–Head and Neck Surgery, Department of Surgery, School of Medicine at the University of Alabama at Birmingham, Birmingham.

**Corresponding Author:** Eben L. Rosenthal, MD, Division of Otolaryngology–Head and Neck Surgery, BDB Ste 563, 1808 7th Ave South, Birmingham, AL 35233 (oto@uab.edu).

**S**urgical salvage after chemoradiation therapy for larynx cancer can be complicated by delayed wound healing. Variables contributing to this complication include underlying tissue changes; unfavorable nutritional status from previously compromised enteric feeding access; suppressed thyroid function; bacterial contamination of the wound bed; and tissue dynamics from swallowing, breathing, and coughing.<sup>1-5</sup> Pharyngocutaneous fistula formation after laryngopharyngectomy is 1 of the most common and also most challenging problems to manage.<sup>6-13</sup> The reported incidence of this complication varies widely based on report, with a recent study from our institution describing an overall rate of 21%.<sup>14</sup> Pharyngocutaneous fistula is often complicated by stomal contamination with risk for aspiration pneumonia and great vessel exposure to pharyngeal secretions. To date, there is a lack of high-level evidence on this subject to help guide our decision making, but it has become well recognized that certain strategies, such as the introduction of vascularized tissue into these wounds and optimizing medical comorbidities, aids in management.<sup>15</sup>

Negative pressure wound therapy is a technique that can be used to promote healing. This technology was developed over 15 years ago and has become increasingly valuable in the management of chronic and acute wounds, contaminated wounds, traumatic tissue loss, surgical dehiscence, ulceration from vascular insufficiency, fistulas, and other indications.<sup>16-26</sup> Current theories on how negative pressure wound therapy is successful include removal of exudate from the wound bed, decrease of interstitial edema, increase in blood flow, increase in granulation formation, decrease in bacterial burden, stimulation of fibroblast and endothelial cell proliferation, mechanical contracture of the wound bed, and mechanical debridement with sponge exchange.

Negative pressure wound therapy generally involves placing a dressing, such as a sponge, into a wound cavity, sealing the area with an adhesive film, and connecting the wound to a vacuum device to deliver a controlled negative pressure to the wound bed. Negative pressure dressings (NPDs) have been previously described in the head and neck in this traditional, externally applied manner.<sup>24,27-36</sup> Recently, a system has been devised to apply negative pressure in an intraluminal or intracavitary fashion to heal rectal abscess cavities that developed after colorectal anastomotic leakage.<sup>37</sup> This technology has also been applied to assist healing of anastomotic leaks in the thorax and abdomen after gastrectomy, iatrogenic esophageal perforation, and esophageal rupture from Boerhaave syndrome.<sup>38-40</sup> Based on these positive reports, we applied this technique in an attempt to potentially optimize pharyngeal reconstruction in high-risk patients, with the major objective of determining safety and feasibility. To our knowledge, this is the first time NPDs have been applied in an intraluminal fashion in the head and neck.

## Methods

The institutional review board at the University of Alabama at Birmingham granted approval for the retrospective review of

all patients undergoing head and neck reconstruction. Medical records were reviewed for all patients with head and neck cancer in whom intraluminal NPDs were used in combination with the introduction of vascularized tissue for pharyngeal reconstruction. From August 2011 to May 2012, 12 patients met these inclusion criteria.

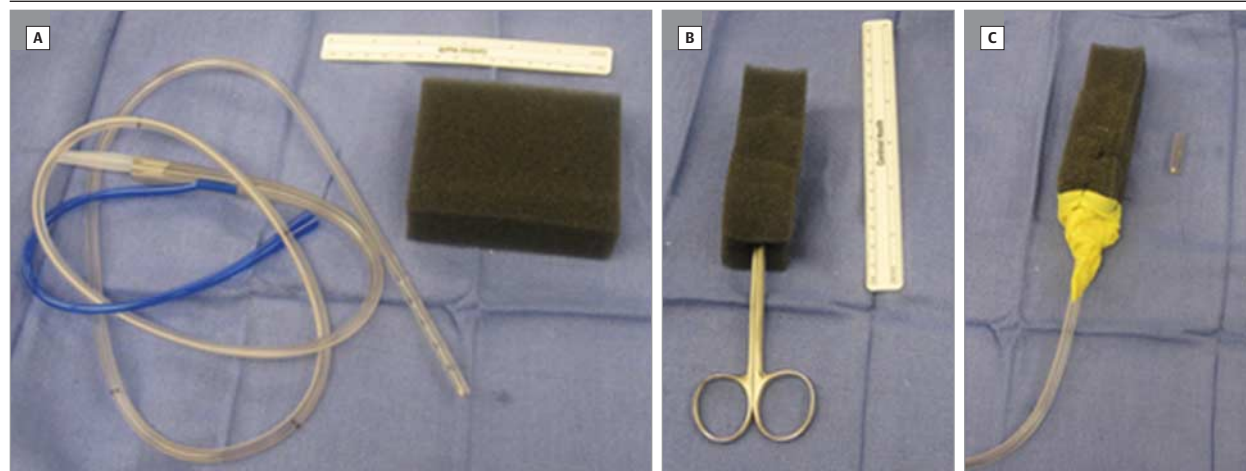
Demographic and clinical data were recorded, including patient age, sex, medical comorbidities, all previous oncologic therapy, operative details, radiologic findings, and full perioperative course of wound healing. Descriptive variables were assessed as mean (SD) data and categorical variables as percentages with significant digits.

## Surgical Technique

Patients in this study underwent concurrent or had previously undergone primary or salvage total laryngectomy with partial or total pharyngectomy. Patients gave written informed consent for surgery, and off-label indications for NPD usage were discussed with them. All procedures were performed in the operating room under general anesthesia with ventilation via cuffed endotracheal tube placed in the tracheostoma. If oncologic ablation was performed at the time of surgery, frozen section pathologic analysis was used to ensure adequate margins. Otherwise, in cases of established pharyngocutaneous fistula, esophagoscopy was performed to ensure that no malignant neoplasm was identified.

We recommend practice with construction of the system before implementation (Figure 1). The typical steps for intraluminal NPD application are illustrated in Figure 2. The nose is topically decongested, and a standard 18F nasogastric tube (NGT) (Kendall) is passed through the nose down into the pharynx and led out of the pharyngeal opening. The defect is measured, and a standard negative pressure wound sponge (VAC Granufoam, KCI) is cut to the appropriate length. We recommend at least 1 cm of intraluminal sponge both superior and inferior to the pharyngeal opening. The sponge diameter should be slightly larger than the diameter of the planned pharyngeal reconstruction at rest but slightly smaller with compression and suction. A stab incision is made in the sponge, and the NGT is inserted, confirming that there are no fenestrations lying outside of the sponge (often the NGT will need to be trimmed). The NGT is then sewn to the sponge with 2-0 silk. Depending on the compliance of the pharynx and the cephalic or caudal location of the pharyngeal repair, often a bolster formed from an occlusive petrolatum gauze dressing, such as Xeroform (Kendall), should be sewn to the cephalic portion of the sponge to maintain adequate suction. The sponge is then withdrawn into an intraluminal position. Closure of the pharynx may then be performed with vascularized tissue (ie, regional or free flap). Suction can be applied intermittently to test the method of closure before final sutures are placed. The NGT should be adequately secured to the nose via tape or transeptal suture. It is important to remember to seal the ventilation port of the NGT. Continuous high-intensity vacuum should be applied to the other port of the NGT, at 125 mm Hg. A canister with less than 100 mL of volume was used to collect secretions from the wound bed. Vacuum tub-

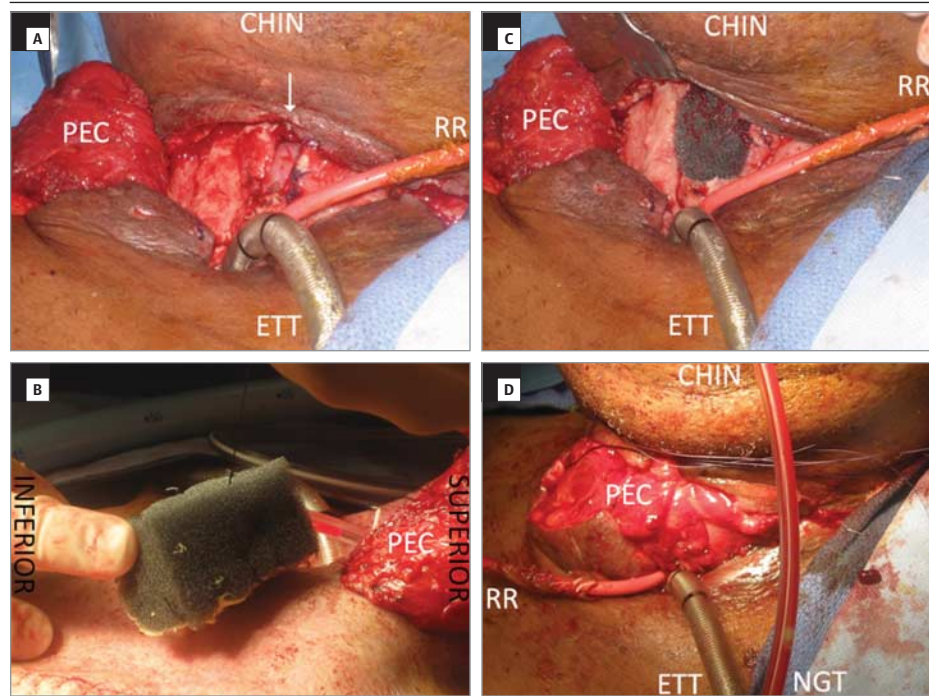
Figure 1. Design of Intraluminal Negative Pressure Wound Therapy System



A, Begin with a standard nasogastric tube (NGT) and standard wound vacuum sponge. The sponge should be trimmed to the appropriate size. B, Scissors or trocar can then be used to create a stab incision in the sponge. C, The NGT is then sized so that no suction fenestrations lie outside of sponge, the NGT is

sewn to sponge, and often a Xeroform bolster is attached as well to create optimal seal in the pharynx. The rulers are in centimeters on one side and inches on the other side.

Figure 2. Fistula Closure Strategy



A, Wound prepared with neck flaps reopened, pharyngeal leak identified (arrow), and pectoral flap (PEC) raised and tunneled into the wound. CHIN indicates chin. A red Robinson rubber catheter (RR) is in place from prior tracheoesophageal puncture. ETT indicates an endotracheal tube in a tracheostoma. B, Profile view of a nasogastric tube (NGT) inserted through the nose and led out of the pharyngeal defect, then secured to sponge. C, Sponge positioned into pharyngeal defect. D, PEC flap sewn into position. The NGT can be seen in this view, where it is traveling down from the nose.

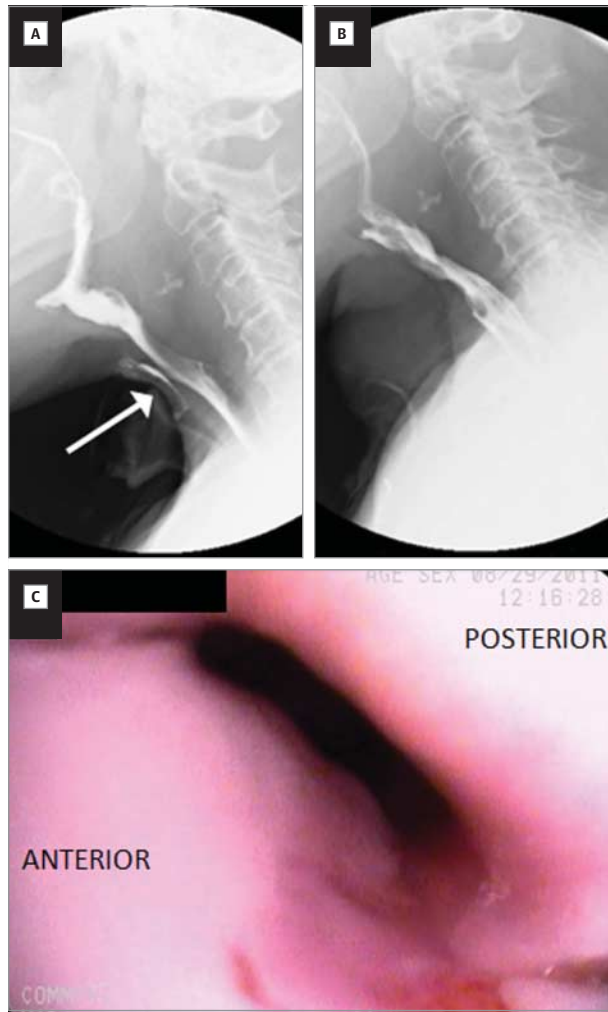
ing can be clamped for patient ambulation, and so forth, similar to techniques for traditional NPDs.

Removal of the sponge is performed under general anesthesia in order to reexamine the wound. This is accomplished by flushing the sponge with normal saline and pulling the NGT back until the sponge can be removed orally. The sponge is then disconnected from the NGT, and the remaining NGT is then pulled out through the nose. Postoperatively, an esophagram is recommended to confirm the endoscopic findings (Figure 3).

## Results

Application of an intraluminal NPD in combination with the introduction of vascularized tissue resulted in successful pharyngeal reconstruction in 11 of 12 patients (92%). The mean (SD) patient age was 63 (8) years, and 7 of 12 were female (58%). All 12 patients had undergone surgery for malignant neoplasms of the upper aerodigestive tract. Seven patients had an established pharyngocutaneous fistula, and an intraluminal NPD was

Figure 3. Confirmation of Pharyngocutaneous Fistula Closure



Preoperative (A) and postoperative (B) radiographic swallow studies demonstrating leak (arrow) and resolution of leak after repair. C, Endoscopy shows granulation at sight of repair with no sign of fistula.

placed at the time of the fistula repair in an attempt to optimize pharyngeal closure. Five high-risk patients had an intraluminal NPD placed in a prophylactic fashion at the time of initial reconstruction after laryngopharyngectomy in an attempt to decrease the chance of pharyngocutaneous fistula.

All 12 patients had at least 1 potential risk factor for compromised wound healing (Table), with most (92%) having 2 or more. Nine patients had been previously treated with radiation therapy, 7 were being treated for hypothyroidism, 4 had diabetes mellitus, and 6 had compromised nutrition status (>10% loss of pre-morbid weight). There was attempt to optimize all comorbidities. The NPD was removed a mean (SD) of 5.8 (1.7) days after placement. The timing of removal was often influenced by access to operating room time, with a goal of 7 days of therapy unless clinically indicated otherwise. One patient had difficulty maintaining an adequate seal and underwent early removal. A second patient's intraluminal NPD was removed early because the sponge was soiled with stom-

ach contents after an episode of nausea and vomiting. No serious adverse events, however, could be attributed to the use of intraluminal NPDs.

#### Optimization of Pharyngocutaneous Fistula Closure With Intraluminal NPD

Seven patients with potential risk factors for inhibited wound healing and an established pharyngocutaneous fistula underwent reconstruction with vascularized tissue and the use of an intraluminal NPD in an attempt to potentially optimize closure (Table). These patients had failed conservative therapy, with time of failure ranging from 2 weeks to 1 year after pharyngocutaneous fistula diagnosis. Defect measurements ranged from 1 to 6 cm<sup>2</sup>. All 7 of these reconstructions used a regional myofascial pectoralis flap.

All 7 patients (100%) had satisfactory closure of the established pharyngocutaneous fistula based on an esophagram at approximately 1 week postoperatively. Six of these 7 patients (86%) resumed and have maintained an oral diet from that point forward. One of these 7 patients (14%) initially had a successful leak repair but later developed a separate area of wound breakdown and a second fistula.

#### Prophylactic Intraluminal NPD

Five patients at high risk for pharyngocutaneous fistula had an intraluminal NPD placed prophylactically at the time of initial pharyngeal reconstruction with vascularized tissue (Table). Two reconstructions were of complex wounds with pharyngeal violation from cancer ablation in the case of salvage laryngectomy stomal recurrence, 1 requiring a free flap in a tubed fashion. Two other cases were salvage total laryngopharyngectomies requiring free flap reconstruction in a tubed fashion. The fifth reconstruction case was a total laryngectomy patch defect in the setting of a patient who had undergone irradiation twice.

Five of 5 patients (100%) were able to resume an oral diet by 3 weeks postoperatively. Three patients had negative results from esophagrams at 1 week postoperatively and were thus able to immediately resume oral intake. One patient had a negative result from an esophagram at 1 week postoperatively (at the time of NPD removal) but developed a neck infection the following week. A second esophagram was then obtained, which identified a 6-mm pharyngocutaneous fistula; therefore, the wound was washed out and a pathway for drainage was established. This closed without further intervention at the 3-week postoperative mark, at which point he resumed oral nutrition. One patient had an esophagram at 1 week indicating a small contained leak, and therefore a previously placed passive drain was left in place. This leak sealed spontaneously without intervention, and this patient also resumed oral nutrition at the 3-week postoperative time point.

## Discussion

Herein, we describe the application of intraluminal NPDs to aid in the prevention or closure of pharyngocutaneous fistulas as an adjunct to conventional techniques. Previous re-

Table. Comparison of Patients Using Intraluminal Negative Pressure Dressings

Patient, No. /Sex/ Age, y	Fistula Size, cm	Previous Therapy	Wound Healing Risk Factors	Indication	Closure Technique	Tx Length, d	Outcome
1/F/68	2 × 3	Salvage TL, BND 1° Closure	CRT DM Hypothyroidism	PCF Failed 1-y conservative tx	PEC	7	Negative results from esophagram PCF closure PO diet at 1 wk
2/M/68	1 × 1	Salvage TL RFFF closure, healed. Stomal recurrence = RND/partial pharyngectomy 1° Closure	CRT Hypothyroidism Malnourished	PCF Failed 2-wk conservative tx	PEC	3 <sup>a</sup>	Negative results from esophagram PCF closure Developed second PCF
3/F/71	1.5 × 2.5	TO carbon dioxide laser excisions ×2; salvage TL, BND 1° Closure	XRT DM	PCF Failed 2-wk conservative tx	PEC	8	Negative results from esophagram PCF closure PO diet at 1 wk
4/M/68	1 × 2	Salvage TL, BND 1° Closure	XRT	PCF Failed 2-mo conservative tx	PEC	3 <sup>a</sup>	Negative results from esophagram PCF closure PO diet at 1 wk
5/F/44	2 × 3	Salvage TL, BND RFFF closure	XRT DM	PCF Failed 3-mo conservative tx	PEC	7	Negative results from esophagram PCF closure PO diet at 1 wk
6/F/60	1 × 4	TL, BND RFFF closure	Hypothyroidism Malnourished	PCF Failed 4-mo conservative tx	PEC	7	Negative results from esophagram PCF closure PO diet at 1 wk
7/M/68	2 × 2	TL, BND 1° Closure	DM Malnourished	PCF Failed 5-mo conservative tx	PEC	4	Negative results from esophagram PCF closure PO diet at 1 wk
8/M/60	NA	Salvage TL, BND RFFF closure, healed Stomal recurrence = partial pharyngectomy	XRT Hypothyroidism	Prophylaxis	RFFF	6	Negative results from esophagram PCF closure PO diet at 1 wk
9/F/73	NA	Salvage TL, BND RFFF closure, healed Stomal recurrence = total pharyngectomy	CRT Hypothyroidism Malnourished	Prophylaxis	Tubed RFFF	5	Negative results from esophagram PCF closure PO diet at 1 wk
10/F/61	NA	TO carbon dioxide laser excisions × 2; salvage TLP	XRT Hypothyroidism Malnourished	Prophylaxis	Tubed RFFF + PEC	7	Positive results from esophagram Conservative tx PCF closure at 3 wk PO diet at 3 wk
11/M/55	NA	TLP, BND	Hypothyroidism Malnourished	Prophylaxis	Tubed rectus FF	7	Negative results from esophagram Positive second esophagram, neck w/o PCF closure at 3 wk PO diet at 3 wk
12/F/64	NA	Salvage TL	XRT Repeated XRT	Prophylaxis	RFFF	6	Negative results from esophagram PCF closure PO diet at 1 wk

Abbreviations: BND, bilateral neck dissections; CRT, chemoradiation therapy; DM, diabetes mellitus; FF, free flap; NA, not applicable; PCF, pharyngocutaneous fistula; PEC, myofascial pectoralis regional flap; PO, postoperative; RFFF, radial forearm free flap reconstruction; RND, radical neck dissection; TL, total

laryngectomy; TLP, total laryngopharyngectomy; TO, transoral; tx, therapy; w/o, washout; XRT, radiation therapy.

<sup>a</sup> Negative pressure dressing removed early.

ports using NPDs in rectal and esophageal anastomotic leaks or abscess cavities suggested the use of intracavitary NPDs in an attempt to potentially optimize pharyngeal reconstruction.<sup>37-40</sup> Although the sample size in this study was small, we feel this novel technique has proven to be feasible after successful application in 12 patients, with a minimum of 6-months' follow-up. There were no serious adverse events associated with its use. This technique added minimal additional effort to the surgeon or postoperative burden to the patient other than the necessity of a second anesthetic for device removal. De-

spite advances in managing pharyngocutaneous fistula, with the current published success rates, there is certainly indication for any adjuvant therapy that could potentially decrease this complication.<sup>6,9,15,41,42</sup>

Patients who underwent intraluminal NPD in combination with the introduction of vascularized tissue experienced a higher than expected rate of successful pharyngeal integrity, allowing them to rapidly return to an oral diet. This retrospective study is prone to selection bias; however, we used this strategy in the "worst of the worst" patients in an at-

tempt to optimize their chance at successful pharyngeal closure. Although the introduction of vascularized tissue alone is often sufficient in the management of pharyngeal closure, in these selected patients, most would agree that the rate of pharyngocutaneous fistula is still considerable.<sup>15</sup> It is unknown if this technique could be used to augment primary closure and avoid introduction of vascularized tissue. As previously described, multiple factors likely contribute to limiting the success of the initial wound-healing phase in these cases. In addition to the proposed mechanisms for accelerated healing associated with NPDs, the application of an intraluminal NPD in this fashion theoretically may reduce salivary exposure of the suture lines, decrease positive pressure from swallowing along the closure, and act as a stent.

There were multiple hypothetical concerns with intraluminal NPDs for pharyngocutaneous fistula that have fortunately not proven to be clinically significant. Although 1 patient required a single esophageal dilation postoperatively, we did not notice circumferential scarring from application of the NPD to the entire lumen. Patient discomfort, anecdotally, has been minimal. Depending on the level of the fistula, tissue compliance, and anatomy of prior reconstructions, perhaps the greatest anticipated obstacle was generation of an adequate seal for the wound vacuum cavity. Again, a seal can be maintained with the addition of an occlusive petrolatum gauze dressing to the cephalic portion of the wound

sponge. Another area of concern when attempting to generate subatmospheric pressure can be if there is a tracheo-esophageal prosthesis or a previously created tracheo-esophageal puncture with feeding tube inserted through it. Fortunately, these potential sites of failure have not proven to be an issue.

This technique would benefit from additional study to measure both short- and long-term outcomes. Patient-perceived subjective data should be collected, as well as a prospective randomized clinical trial with appropriate controls designed. Such a study should result in a higher likelihood of accurate conclusion in regard to the efficacy of intraluminal NPDs at improving pharyngeal reconstructive outcomes. Safety should be continued to be monitored, because certainly this is an off-label use of technology. Cost analysis for intraluminal NPDs should also be investigated to justify the additional charges associated with the device and a second anesthetic.

## Conclusions

Intraluminal negative pressure wound therapy is feasible and safe. Future research should be conducted to determine its potential in optimizing pharyngeal reconstruction in high-risk patients.

### ARTICLE INFORMATION

**Submitted for Publication:** May 28, 2013; final revision received October 13, 2013; accepted November 3, 2013.

**Published Online:** December 26, 2013.  
doi:10.1001/jamaoto.2013.6143.

**Author Contributions:** Dr Asher had full access to all of the data in the study and takes responsibility for the integrity of the data and the accuracy of the data analysis.

**Study concept and design:** Asher, White, Magnuson, Rosenthal.

**Acquisition of data:** Asher, Illing, Carroll.

**Analysis and interpretation of data:** Asher, Magnuson, Rosenthal.

**Drafting of the manuscript:** Asher.

**Critical revision of the manuscript for important intellectual content:** All authors.

**Statistical analysis:** Asher.

**Administrative, technical, or material support:** Asher, Illing, Carroll, Magnuson, Rosenthal.

**Study supervision:** Asher, White, Magnuson, Rosenthal.

**Conflict of Interest Disclosures:** None reported.

**Previous Presentation:** This study was a poster presentation at the American Head and Neck Society's Section Meeting at the Combined Otolaryngology Society Meetings; April 11, 2013; Orlando, Florida.

### REFERENCES

1. Hom DB, Adams GL, Monyak D. Irradiated soft tissue and its management. *Otolaryngol Clin North Am.* 1995;28(5):1003-1019.

2. Moore MJ. The effect of radiation on connective tissue. *Otolaryngol Clin North Am.* 1984;17(2):389-399.

3. Sessler AM, Esclamado RM, Wolf GT. Surgery after organ preservation therapy: analysis of wound complications. *Arch Otolaryngol Head Neck Surg.* 1995;121(2):162-165.

4. Weber RS, Berkey BA, Forastiere A, et al. Outcome of salvage total laryngectomy following organ preservation therapy: the Radiation Therapy Oncology Group Trial 91-11. *Arch Otolaryngol Head Neck Surg.* 2003;129(1):44-49.

5. Ganly I, Patel S, Matsuo J, et al. Postoperative complications of salvage total laryngectomy. *Cancer.* 2005;103(10):2073-2081.

6. Andrades P, Pehler SF, Baranano CF, Magnuson JS, Carroll WR, Rosenthal EL. Fistula analysis after radial forearm free flap reconstruction of hypopharyngeal defects. *Laryngoscope.* 2008;118(7):1157-1163.

7. Hui Y, Wei WI, Yuen PW, Lam LK, Ho WK. Primary closure of pharyngeal remnant after total laryngectomy and partial pharyngectomy: how much residual mucosa is sufficient? *Laryngoscope.* 1996;106(4):490-494.

8. Funk K, Teknos TN, Vandenberg CD, et al. Prevention of wound complications following salvage laryngectomy using free vascularized tissue. *Head Neck.* 2007;29(5):425-430.

9. Withrow KP, Rosenthal EL, Gourin CG, et al. Free tissue transfer to manage salvage laryngectomy defects after organ preservation failure. *Laryngoscope.* 2007;117(5):781-784.

10. Patel UA, Keni SP. Pectoralis myofascial flap during salvage laryngectomy prevents

pharyngocutaneous fistula. *Otolaryngol Head Neck Surg.* 2009;141(2):190-195.

11. Gil Z, Gupta A, Kummer B, et al. The role of pectoralis major muscle flap in salvage total laryngectomy. *Arch Otolaryngol Head Neck Surg.* 2009;135(10):1019-1023.

12. Teknos TN, Myers LL, Bradford CR, Chepeha DB. Free tissue reconstruction of the hypopharynx after organ preservation therapy: analysis of wound complications. *Laryngoscope.* 2001;111(7):1192-1196.

13. Rosenthal E, Couch M, Farwell DG, Wax MK. Current concepts in microvascular reconstruction. *Otolaryngol Head Neck Surg.* 2007;136(4):519-524.

14. White HN, Golden B, Sweeny L, Carroll WR, Magnuson JS, Rosenthal EL. Assessment and incidence of salivary leak following laryngectomy. *Laryngoscope.* 2012;122(8):1796-1799.

15. Hanasono MM, Lin D, Wax MK, Rosenthal EL. Closure of laryngectomy defects in the age of chemoradiation therapy. *Head Neck.* 2012;34(4):580-588.

16. Ubbink DT, Westerbos SJ, Evans D, Land L, Vermeulen H. Topical negative pressure for treating chronic wounds. *Cochrane Database Syst Rev.* 2008;(3):CD001898.

17. Vidrine DM, Kaler S, Rosenthal EL. A comparison of negative-pressure dressings versus Bolster and splinting of the radial forearm donor site. *Otolaryngol Head Neck Surg.* 2005;133(3):403-406.

18. Bovill E, Banwell PE, Teot L, et al; International Advisory Panel on Topical Negative Pressure. Topical negative pressure wound therapy: a review of its role and guidelines for its use in the management of acute wounds. *Int Wound J.* 2008;5(4):511-529.

19. Peinemann F, Sauerland S. Negative-pressure wound therapy: systematic review of randomized controlled trials. *Dtsch Arztebl Int*. 2011;108(22):381-389.
20. Xie X, McGregor M, Dendukuri N. The clinical effectiveness of negative pressure wound therapy: a systematic review. *J Wound Care*. 2010;19(11):490-495.
21. Mouës CM, Heule F, Hovius SE. A review of topical negative pressure therapy in wound healing: sufficient evidence? *Am J Surg*. 2011;201(4):544-556.
22. Fries CA, Jeffery SL, Kay AR. Topical negative pressure and military wounds: a review of the evidence. *Injury*. 2011;42(5):436-440.
23. Leininger BE, Rasmussen TE, Smith DL, Jenkins DH, Coppola C. Experience with wound VAC and delayed primary closure of contaminated soft tissue injuries in Iraq. *J Trauma*. 2006;61(5):1207-1211.
24. Geiger S, McCormick F, Chou R, Wandel AG. War wounds: lessons learned from Operation Iraqi Freedom. *Plast Reconstr Surg*. 2008;122(1):146-153.
25. Fang R, Dorlac WC, Flaherty SF, et al. Feasibility of negative pressure wound therapy during intercontinental aeromedical evacuation of combat casualties. *J Trauma*. 2010;69(suppl 1):S140-S145.
26. Krug E, Berg L, Lee C, et al; International Expert Panel on Negative Pressure Wound Therapy [NPWT-EP]. Evidence-based recommendations for the use of Negative Pressure Wound Therapy in traumatic wounds and reconstructive surgery: steps toward an international consensus. *Injury*. 2011;42(suppl 1):S1-S12.
27. Palm HG, Hauer T, Simon C, Willy C. Vacuum-assisted closure of head and neck wounds [in German]. *HNO*. 2011;59(8):819-830.
28. Rosenthal EL, Blackwell KE, McGrew B, Carroll WR, Peters GE. Use of negative pressure dressings in head and neck reconstruction. *Head Neck*. 2005;27(11):970-975.
29. Shreenivas S, Magnuson JS, Rosenthal EL. Use of negative-pressure dressings to manage a difficult surgical neck wound. *Ear Nose Throat J*. 2006;85(6):390-391.
30. Kelly TF, Banks SB, Miller LA. Straightforward management of a large pediatric scalp degloving injury in a combat zone. *J Oral Maxillofac Surg*. 2010;68(6):1411-1414.
31. Marathe US, Sniezek JC. Use of the vacuum-assisted closure device in enhancing closure of a massive skull defect. *Laryngoscope*. 2004;114(6):961-964.
32. Nouraei SA, Hodgson EL, Malata CM. Cervicofacial necrotising fasciitis: management with neck dissection and topical negative pressure. *J Wound Care*. 2003;12(4):147-149.
33. Garas G, Ifeacho S, Millard R, Tolley N. Melioidosis and the vacuum-assisted closure device: a rare cause of a discharging neck wound, and a new approach to management. *J Laryngol Otol*. 2010;124(9):1021-1024.
34. Andrews BT, Smith RB, Goldstein DP, Funk GF. Management of complicated head and neck wounds with vacuum-assisted closure system. *Head Neck*. 2006;28(11):974-981.
35. Dhir K, Reino AJ, Lipana J. Vacuum-assisted closure therapy in the management of head and neck wounds. *Laryngoscope*. 2009;119(1):54-61.
36. Andrews BT, Smith RB, Hoffman HT, Funk GF. Orocutaneous and pharyngocutaneous fistula closure using a vacuum-assisted closure system. *Ann Otol Rhinol Laryngol*. 2008;117(4):298-302.
37. Riss S, Stift A, Meier M, Haiden E, Grünberger T, Bergmann M. Endo-sponge assisted treatment of anastomotic leakage following colorectal surgery. *Colorectal Dis*. 2010;12(7 online):e104-e108.
38. Loske G, Müller C. Vacuum therapy of an esophageal anastomotic leakage: a case report [in German]. *Zentralbl Chir*. 2009;134(3):267-270.
39. Loske G, Schorsch T, Müller C. Endoscopic vacuum sponge therapy for esophageal defects. *Surg Endosc*. 2010;24(10):2531-2535.
40. Loske G, Schorsch T, Müller C. Intraluminal and intracavitary vacuum therapy for esophageal leakage: a new endoscopic minimally invasive approach. *Endoscopy*. 2011;43(6):540-544.
41. Iteld L, Yu P. Pharyngocutaneous fistula repair after radiotherapy and salvage total laryngectomy. *J Reconstr Microsurg*. 2007;23(6):339-345.
42. Yu P. One-stage reconstruction of complex pharyngoesophageal, tracheal, and anterior neck defects. *Plast Reconstr Surg*. 2005;116(4):949-956.