02/2014

Vivano® Spectrum

Convincing case examples of negative-pressure wound therapy.

Abdominal · Traumatic · Chronic · Burns

Editorial details

Published by
PAUL HARTMANN AG, P. O. Box 1420,
89504 Heidenheim, Telephone: +49 7321 36–0,
www.hartmann.info

Issue: 02/2014
Photographs: M. Hutàn (p. 13), M. Boucher (p. 15), S. Shlyapnikov (p.17), R. Škuta (p. 19), S.G. Shapovalov (p. 21), V.N. Obolensky (p. 23), L. Veverkova (p. 25), M. Ali (p. 27), P. W. Trzeciak (p. 29), V.V. Zavatsky (p. 31), C. Toth (p. 33), A. Ulici (p. 35)
Title: Frank Bauer

Editorial

Dear colleagues,

Following the first edition of "Vivano® Spectrum" it is my great pleasure to introduce the second edition.

The first edition received an enthusiastic response from clinicians who participated in the Vivano® Congress and colleagues who "merely" read through "Vivano® Spectrum". The spirit of sharing knowledge is essential when aiming for better patient outcomes, and your responses showed that there is a need in this regard.

In this edition, you will find a selection of cases, reviews and studies which were presented at the Vivano® Congress 2014 in Nuremberg. The special emphasis in this Vivano® Spectrum is on the open abdomen – clinically a complex situation associated with significant mortality. The underlying causes for patients requiring open abdomen therapy include abdominal injuries, trauma, sepsis, re-laparotomy and damage control. Several surgical techniques have been established to provide temporary closure. Out of these, specialized NPWT treatment protocols provide efficient and effective therapeutic options.

While it is impossible to cover the entire topic in this edition, we have selected case reports which illustrate different clinical approaches, and overviews highlighting the various dimensions to consider when treating patients with open abdomen.
Here again, clinical expertise is crucial. Sharing knowledge is essential for propagating best practices.

You will also find reports on the application of NPWT in connection with other clinical indications. We hope that this will provoke discussions and reflections on optimizing treatment algorithms to enhance NPWT outcomes. Thus, this issue is about you – about your experience and expertise and about your ideas for improving therapies.
So, if you come across clinical cases your colleagues should know about, new ideas on how to use NPWT, or topics you would like to see discussed, take the initiative and let your colleagues know. Mrs Kristin Hackel (kristin.hackel@hartmann.info) is your contact person.

Please feel invited to share!

Kind regards,

Prof. Hans Smola, MD

Content

Review of the clinical and economic evidence regarding the application of NPWT in Open Abdomen

Daniela Kaspar PhD
Manager Clinical Application Studies, PAUL HARTMANN AG, Heidenheim, Germany

Open Abdomen – Still associated with high mortality

Most laparotomies end with the closure of abdominal fascia. If, however, restoration of normal physiology is of prior importance as opposed to definive repair of injury, the abdomen will be left open in successive surgical procedures before definive closure (1). While over the last 20 years, management with Open Abdomen (OA) has been increasingly applied (2) but, it is still associated with challenging complications, and the mortality reaches a rate of more than 30% (3). There are in general three scenarios which could be prevented by, or which are managed with initiation of OA (3):

- Patients with peritonitis when infection causes bowel odema
- Patients with abdominal compartment syndrome where increased intra-abdominal pressure requires decompressive laparostomy
- Patients with trauma and intra-abdominal bleeding where damage control surgery is required in order to control bleeding.

The need to manage an increasing number of OAs has resulted in multiple different approaches in order to provide temporary closure followed by closure of the abdominal fascia. Boele van Hensbroek (2009) presented several techniques and assessed those techniques which are associated with the highest delayed primary fascial closure rate and the lowest mortality rate. In the comparison of negative pressure wound therapy (NPWT), vacuum pack, Wittmann patch, dynamic retention suture, Bogotá bag, mesh/sheet, loose packing with standard wound dressing, skin approximation with towel clips or running suture, and zipper, NPWT was found to be associated with one of the lowest mortality rates (18%) and one of the highest final closure rates (60%) (3). These rates were confirmed by a systematic review by Quyn et al. (2012), who calculated a mortality rate of 22% and a fascial closure rate of 58% (4). NPWT also appears to be an effective combination to minimise the risk of bowel fistulas, the most critical serious complication of OA (5).

NPWT – Evidence for its efficiency in OA

Since the early 1990s, when negative pressure wound therapy was developed independently by Fleischmann, Morykwas and Argenta in Germany and the USA (6-8), NPWT has found its way into a wide range of wound atiologies. From 2006 onward, the efficiency of NPWT in the management of OA has been studied by comparative trials in order to evaluate its safety, efficiency and cost effectiveness. Although there is still a gap with regard to clinical evidence (9), NPWT now forms an integral part of recommendations for the management of chronic and acute wounds as well as of OA (10-13).

Randomised controlled trial – a rare design for studies of NPWT in OA

Due to difficulties in performing high quality randomized studies in patients with OA, there is still a gap as regards clinical evidence. The main limitation is time, in particular when the prevalence of patients of interest is low. Patients with open abdomen are a diverse group with distinct diseases. Their numbers are low, and even in high-volume centers no more than 5-10 cases per year occur (14). Only one prospective randomised controlled trial has yet been performed which compared abdominal NPWT with an alternative treatment modality. In this trial, Bee et al. (2008) treated patients with mostly traumatic wounds

requiring temporary abdominal closure either with polyglactin mesh, vacuum pack technique or NPWT (15). Considering that there were no differences with regard to fascial closure and incidence of fistulas, the authors concluded that costs should be weighed when selecting the method for temporary closure.

Current RCTs on NPWT in Open Abdomen

Currently there is one ongoing RCT with the title "Vacuum-Therapy in Open Abdomen Treatment - Randomized Pilot-Trial Comparing Fascial Closure and Survival with 'Vacuum-Pack'-Technique vs. 'Abdominal Dressing' registered on www.clinicaltrials.gov. The primary purpose of the study is to determine whether two vacuum-wound-dressing techniques (the so called "abdominal dressing" versus "vacuum-pack-technique") are equally effective in the treatment of Open Abdomen. Enrolment of the 20 patients to be included started in February 2010, and end of recruitment was expected for August 2014.

Prospective comparative non-randomized trial – a biased study design?

In a prospective, multicentre, non-randomized study, Cheatham et al. (2013) compared an open abdomen NPWT system with Barker's vacuum-packing technique in surgical and trauma patients requiring Open Abdomen management (16). According to the results, NPWT reduced the mortality rate (14% versus 30%) and increased the fascial closure rate (69% versus 51%) compared to the alternative treatment.
The limitation of this study was that half of the patients had been recruited from hospitals where physicians decided according to the patient 's need, whether he or she was going to get NPWT or the alternative treatment. Therefore, patient recruitment may have been biased, although patients of both groups were comparable at baseline and there was no financial interest behind the study.
Another study design possibility that can be applied when introduction of a parallel control group may be unfeasible or unethical is the use of a propensity score which helps to create a matched-pairs sample to estimate effects between the groups. This was realised by Carlson et al. (17), who compared NPWT and the alternative therapies (Bogota bag, prosthetic mesh, dynamic retention suture, simple packing or stoma bag) in the management of OA. When analysing the 187 matched-pairs, they found no significant differences with regard to death, intestinal fistula and other parameters between those treated with and those not treated with NPWT. The limitation of this study was, however, that patients at baseline were not comparable with regard to their disease severity.

Retrospective trials – the real-life clinical practice

Meanwhile, most clinical evidence came from real-life clinical practice, in the form of retrospective clinical studies. These trials generally either used retrospective data for controls and collected data prospectively for NPWT (prospective design with historical controls), or they used retrospective data for both groups in order to compare NPWT with alternative treatment methods (14, 18-22). In order to characterise patients and ensure that there were no differences between study groups at baseline, scores were used to evaluate disease severity (APACHE, SOFA, ISS, SAPS). This study design requires only a small number of patients, because data partly already exist. On the other

hand, it takes into account ethical concerns of physicians who are convinced of the advantages of NPWT and do not want to apply standard therapy anymore, particularly in severe cases. Most of the studies found a reduction in mortality (14, 18, 19, 21) and in hospital stay (19, 20) with the use of NPWT compared to alternative therapies. The study design has limitations: The use of historical controls may lead to bias because of general changes and innovations occurring in a hospital over time.

NPWT – Recommendation for criticaly ill patients with OA

Though high-quality randomized trials are still lacking, NPWT now forms an integral part of GRADE recommendations (12, 13) which are graded according to balance between benefits, risks, burden, and cost as well as according to the quality of evidence (23). In a consensus paper from the World Society of the Abdominal Compartment Syndrome, the GRADE system was used to provide consistency in identifying and rating the quality of available evidence and the strength of management suggestions and recommendations (12). According to the consensus statements, it was recommended that for critically ill or injured patients with open abdominal wounds, strategies utilising negative pressure wound therapy should be used.

Economic view of NPWT

NPWT is often perceived to be more expensive than advanced wound care. This perception, however, is based more on unit price considerations than on a comparison of the total treatment cost (24). Banasiewicz et al. (2014) evaluated the clinical and economic effects of NPWT compared to standard treatment (dynamic sutures, abdominal zip, situational stitches) in patients with Open Abdomen (25). In his retrospective study, he found a reduced mortality (17.6% versus 45%), length of hospital stay (26 days versus 43 days), time of hospitalisation in intensive care (13 days versus 22 days), time of antibiotic treatment (20 days versus 28 days) and a reduced occurrence of complications such as fistulas. Fascial closure had been possible in 13 patients (76%) treated with NPWT compared to 4 patients (20%) treated with standard treatment. According to the economic analysis that considered patient-specific costs as well as hospital costs, the total cost of treatment was remarkably lower for patients treated with NPWT compared to standard treatment. In addition, the earlier patients received NPWT, the more remarkable was the difference. Similar findings were reported by Othman (2012) in her literature review on the clinical effectiveness and cost effectiveness of NPWT in chronic wound management (26).

Conclusion – Appropriate patient assessment to achieve the maximum clinical and economic benefit

Based on the growing clinical and economic evidence in support of NPWT in the management of OA, as well as in the light of the fact that physicians are increasingly convinced of the advantages of NPWT, there is a need for training and education, on one hand, cope with the technical demands of the therapy, and on the other hand, to be able to assess the individual patient's need for NPWT, with the aim of

- guaranteeing that every patient has the opportunity to benefit from NPWT
- ensuring economic utilisation of resources, and
- achieving the maximum benefit with this treatment.

References:

1. Ferreira F, Barbosa E, Guerreiro E, Fraga GP, Nascimento B, Jr., Rizoli S. Sequential closure of the abdominal wall with continuous fascia traction (using mesh or suture) and negative pressure therapy. Rev Col Bras Cir 2013; 40(1):85-9 LID - S0100-699120.
2. Cheatham ML, Safcsak K. Is the evolving management of intra-abdominal hypertension and abdominal compartment syndrome improving survival? Crit Care Med 2010; 38(2):402-07.
3. Boele van HeP, Wind J, Dijkgraaf MG, Busch OR, Goslings JC. Temporary closure of the open abdomen: a systematic review on delayed primary fascial closure in patients with an open abdomen. World J Surg 2009; 33(2):199-207 LID - 10.1007/s0.
4. Quyn AJ, Johnston C, Hall D, Chambers A, Arapova N, Ogston S, et al. The open abdomen and temporary abdominal closure systems-historical evolution and systematic review. Colorectal Dis 2012; 14(8):e429-38 LID - 10.1111/j.1.
5. Becker HP, Willms A, Schwab R. Small bowel fistulas and the open abdomen. Scand J Surg 2007; 96(4):263-71.
6. Fleischmann W, Strecker W, Bombelli M, Kinzl L. [Vacuum sealing as treatment of soft tissue damage in open fractures]. Unfallchirurg 1993; 96(9):488-92.
7. Argenta LC, Morykwas MJ. Vacuum-assisted closure: a new method for wound control and treatment: clinical experience. Ann Plast Surg 1997; 38(6):563-76; discussion 577.
8. Morykwas MJ, Argenta LC, Shelton-Brown EI, McGuirt W. Vacuum-assisted closure: a new method for wound control and treatment: animal studies and basic foundation. Ann Plast Surg 1997; 38(6):553-62.
9. Peinemann F, Sauerland S. Negative-pressure wound therapy: systematic review of randomized controlled trials. Dtsch Arztebl Int 2011; 108(22):381-9 LID - 10.3238/arzt.
10. Krug E, Berg L, Lee C, Hudson D, Birke-Sorensen H, Depoorter M, et al. Evidence-based recommendations for the use of Negative Pressure Wound Therapy in traumatic wounds and reconstructive surgery: steps towards an international consensus. Injury 2011; 42 Suppl 1:S1-12 LID - 10.1016/S00.
11. Vig S, Dowsett C, Berg L, Caravaggi C, Rome P, Birke-Sorensen H, et al. Evidence-based recommendations for the use of negative pressure wound therapy in chronic wounds: steps towards an international consensus. J Tissue Viability 2011; 20 Suppl 1:S1-18 LID - 10.1016/j.j.
12. Kirkpatrick AW, Roberts DJ, De Waele J, Jaeschke R, Malbrain ML, De Keulenaer B, et al. Intra-abdominal hypertension and the abdominal compartment syndrome: updated consensus definitions and clinical practice guidelines from the World Society of the Abdominal Compartment Syndrome. Intensive Care Med 2013; 39(7):1190-206 LID - 10.1007/s0.
13. Bjorck M, Wanhainen A. Management of abdominal compartment syndrome and the open abdomen. Eur J Vasc Endovasc Surg 2014; 47(3):279-87 LID - 10.1016/j.e.
14. Hutan M, Hutan M, Skultety J, Sekac J, Koudelka P, Prochotsky A, et al. Use of intraabdominal VAC (Vacuum Assisted Closure) lowers mortality and morbidity in patients with open abdomen. Bratisl Lek Listy 2013; 114(8):451-54.
15. Bee TK, Croce MA, Magnotti LJ, Zarzaur BL, Maish GO 3r, Minard G, et al. Temporary abdominal closure techniques: a prospective randomized trial comparing polyglactin 910 mesh and vacuum-assisted closure. J Trauma 2008; 65(2):337-42; discussion 342-4.
16. Cheatham ML, Demetriades D, Fabian TC, Kaplan MJ, Miles WS, Schreiber MA, et al. Prospective study examining clinical outcomes associated with a negative pressure wound therapy system and Barker's vacuum packing technique. World J Surg 2013; 37(9):2018-30 LID - 10.1007/s00.
17. Carlson GL, Patrick H, Amin AI, McPherson G, MacLennan G, Afolabi E, et al. Management of the open abdomen: a national study of clinical outcome and safety of negative pressure wound therapy. Ann Surg 2013; 257(6):1154-9 LID - 10.1097/SLA.
18. Wild T, Stortecky S, Stremitzer S, Lechner P, Humpel G, Glaser K, et al. [Abdominal dressing - a new standard in therapy of the open abdomen following secondary peritonitis?]. Zentralbl Chir 2006; 131 Suppl 1:S111-14.
19. Batacchi S, Matano S, Nella A, Zagli G, Bonizzoli M, Pasquini A, et al. Vacuum-assisted closure device enhances recovery of critically ill patients following emergency surgical procedures. Crit Care 2009; 13(6):R194 LID- 10.1186/cc8193 [doi.
20. Baharestani MM, Gabriel A. Use of negative pressure wound therapy in the management of infected abdominal wounds containing mesh: an analysis of outcomes. Int Wound J 2011; 8(2):118-25 LID - 10.1111/j.1.
21. Willms A, Gusgen C, Schreyer C, Becker HP, Schwab R. [Prevention of small bowel fistulas during open abdominal treatment: lessons learned]. Zentralbl Chir 2011; 136(6):592-7 LID - 10.1055/s-00.
22. Frazee RC, Abernathy SW, Jupiter DC, Hendricks JC, Davis M, Regner JL, et al. Are commercial negative pressure systems worth the cost in open abdomen management? J Am Coll Surg 2013; 216(4):730-3; discussion 733-5.
23. Guyatt GH, Oxman AD, Vist GE, Kunz R, Falck-Ytter Y, Alonso-Coello P, et al. GRADE: an emerging consensus on rating quality of evidence and strength of recommendations. BMJ 2008; 336(7650):924-6 LID - 10.1136/bmj.
24. Ousey K, Milne J. Focus on negative pressure: exploring the barriers to adoption. Br J Community Nurs 2010; 15(3):121-24.
25. Banasiewicz T, Cybulka B, Iqbal A, Francuzik W, Linder J, Drews M. Clinical and Economic Benefit of Negative Pressure Wound Therapy in the Treatment of Open Abdomen. Negative Pressure Wound Therapy 2014; 1(2):39-47.
26. Othman D. Negative pressure wound therapy literature review of efficacy, cost effectiveness, and impact on patients' quality of life in chronic wound management and its implementation in the United kingdom. Plast Surg Int 2012; 2012:374398 LID-10.1155/2012/374398.

Clinical and economic benefits of NPWT

Tomasz Banasiewicz
Poznan University of Medical Sciences, Poznan, Poland

Aim of the study

Retrospective comparative study in order to evaluate the clinical and economic benefits of negative pressure wound therapy (NPWT) in patients with open abdomen in a medical setting.

Patients

A total of 37 patients treated for open abdomen be-tween 2009–2012 were included, of whom 20 underwent standard therapy and 17 received NPWT. The NPWT group was in turn subdivided into patients with NPWT initiation during the first 5 days after diagnosis/admission (7) and those later than 5 days (10).

Wounds

The patients had complicated open lower abdominal wounds, and thus a very poor clinical status. The two treatment groups were homogeneous with very similar general clinical conditions. The patients in the NPWT subgroups likewise exhibited very similar clinical conditions.

Wound treatment

Standard therapy involved closing the abdomen by zipping/with temporary sutures, while the second group underwent NPWT.

Results

The complications were more effectively reduced by NPWT compared to standard therapy, with a shorter hospital (26 vs. 43 days) and intensive care stay (13 vs. 22 days). Although wound dressing costs were higher in NPWT patients (€ 1,741 vs. € 525 per patient), this was a minor aspect, considering that the total treatment costs for an NPWT patient amounted to only 67% of those for a standard-treatment patient. Interestingly, both the hospital and patient-specific costs were lower for NPWT treatment. Not only was the mortality rate lower on NPWT treatment (18 vs. 45%), but the cost per saved life (= total cost of all patients treated/number of patients who survived) was only 45% of that for standard treatment. Initiating NPWT earlier (first 5 days compared to >5 days) resulted in a further improvement in the condition of the patient, with slightly shorter hospital (22.7 vs. 28.7 days) and intensive care stays (12 vs. 14 days), lower total cost (€ 9,803 vs. € 13,095), lower mortality (14 vs. 20%) and a 30% reduction in the cost per saved life.

Conclusion

Although the number of patients was not large enough to show a statistical effect, the results indicated that healing with NPWT appeared more effective at less cost, leading to lower mortality and a better quality of life. NPWT should be initiated immediately on diagnosis/admission rather than as a last resort, which has become our current policy.

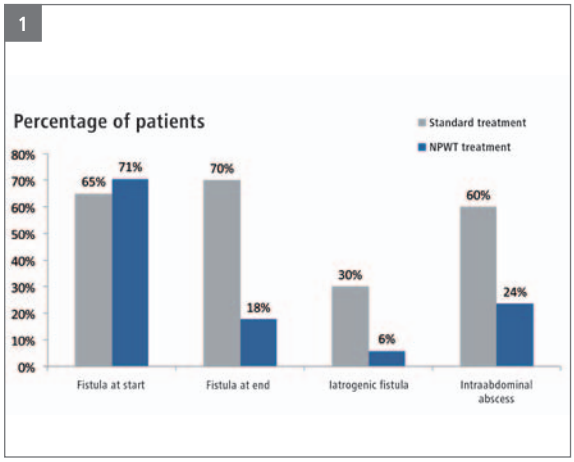

Clinical results: Improvement in complications.

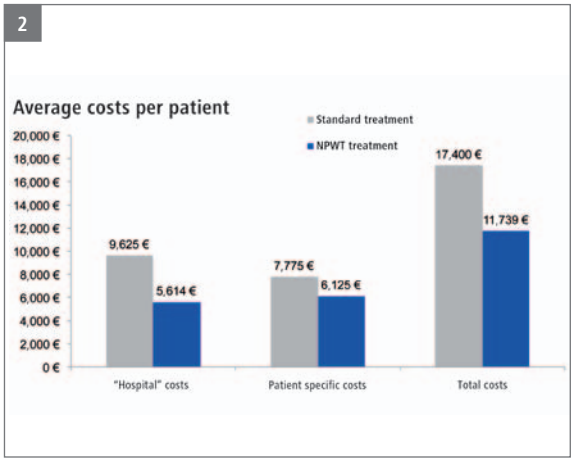

Costs: Overall treatment costs.

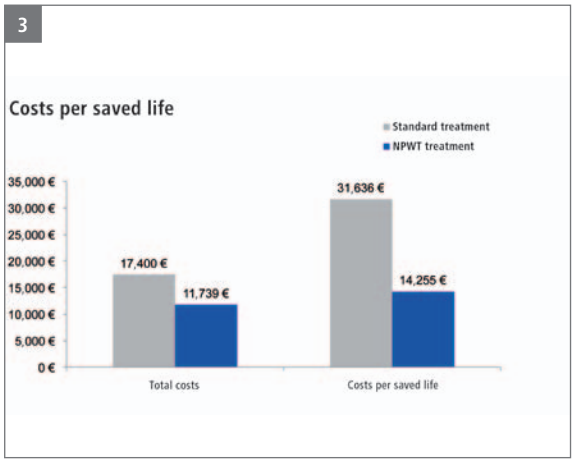

Cost-effectiveness: Costs per saved life.

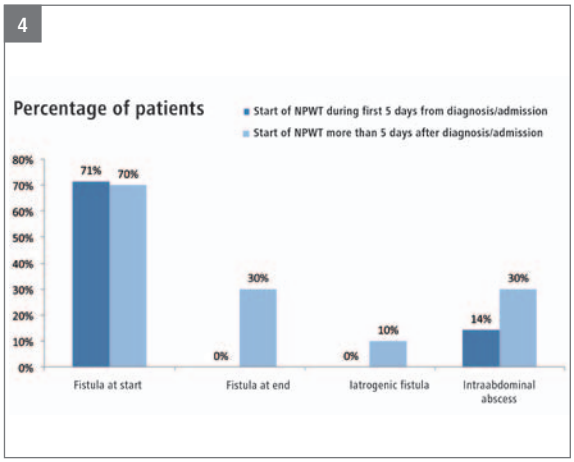

Clinical results: Improvement in complications in early vs. late NPWT.

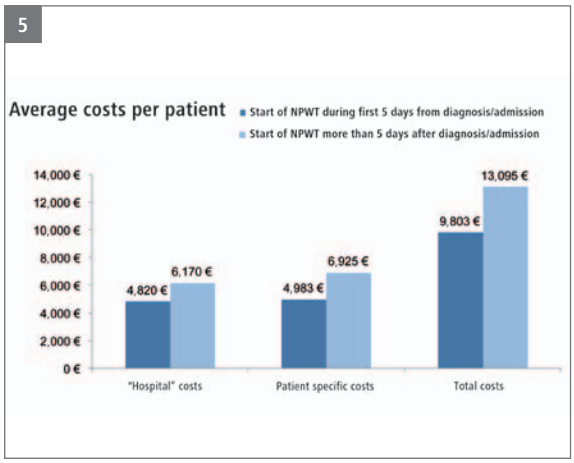

Costs: Overall treatment costs in early vs. late NPWT.

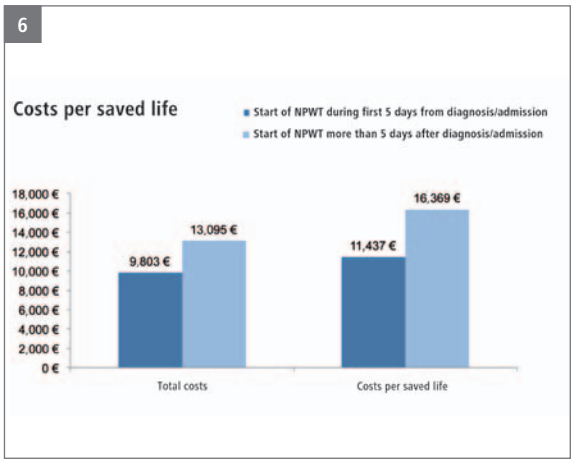

Cost-effectiveness: Costs per saved life in early vs. late NPWT.

Combining prosthetic material and NPWT in giant abdominal wall defect reconstruction

Martin Hutàn
University Hospital of St. Cyril and Methodius, Bratislava, Slovakia

Three obese patients with very large abdominal wall defects requiring reconstruction following hernia operations.

Patient anamnesis

Standard reconstruction surgery cannot be performed when tissue transfer is impossible because of large-scale abdominal tissue loss and massive wound infection. Three patients fitting this scenario were treated. Patient 1 had presented for an operation and small ventral hernia repair. A large part of the abdominal wall of Patient 2 (male) consisted of hernia sites, which after resection resulted in a large defect. Patient 3 (female) required surgery for a suspected gallbladder tumour. Part of the abdominal wall consisted of hernial sacs requiring resection, resulting in a very large defect.

Wound anamnesis

Necrotising fasciitis was found in the abdominal wall of Patient 1. Following resection, sepsis developed and multiple organ failure occurred. The patient required sedation and ventilation. The wounds of Patients 2 and 3 were likewise too large for standard reconstruction surgery.

Aim of the treatment

Application of negative pressure therapy (NPWT) in combination with prosthetic material as a "salvage technique" when a standard reconstruction technique is not feasible.

Wound treatment

Defects were covered using bi-faced polypropylene nets with a hydrophilic layer, and NPWT was applied to accelerate granulation and prevent graft infection. Patient 1 underwent necrectomy, and after 12 changes of negative pressure, granulation was very good, allowing split skin grafting. Three redressings were performed, which controlled the infection, and the patient recovered from the sepsis. In Patient 2, sublay mesh with a hydrophilic substance and NPWT were applied to save part of the skin. However, the skin became necrotic. The necrotic skin was excised and the defect was treated further with mesh and NPWT. Sufficient granulation tissue developed for split skin grafting, and the patient healed. Patient 3 required three polypropylene nets of 20 cm × 30 cm each. Application of NPWT induced granulation, allowing split skin grafting and resulting in eventual healing with very good abdominal wall functionality. No fistula complications were reported during follow-up.

Conclusion

Application of NPWT in combination with bi-faced polypropylene nets should be regarded as a salvage technique. It proved life-saving in these patients and minimised the complications resulting from the absence of an abdominal wall.

Patient 2: Application of NPWT.

Patient 2: Granulation over the mesh.

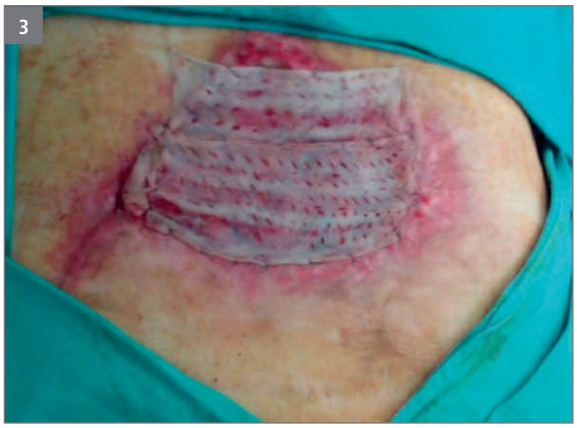

Patient 2: Split skin graft.

Patient 3: Polypropylene nets inserted into the abdominal wall defect.

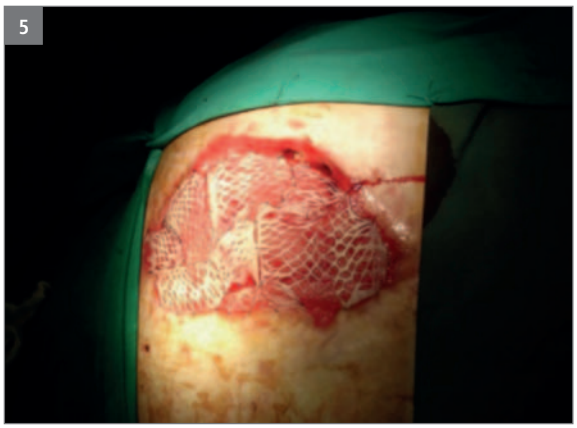

Patient 3: Split skin graft of over granulated defect.

Patient 3: Healed defect with very good functionality of the abdominal wall.

Laparostomy with enterocutaneous fistula

Dr. Marc Boucher
Bethesda Hospital, Duisburg, Germany

A 58-year-old woman developed peritonitis and small bowel lesions after the construction of a terminal descendostomy.

Patient anamnesis

The patient suffered from advanced cervical carcinoma with a tumour in the small pelvis causing intestinal obstruction due to rectostenosis. After partial proctectomy, a terminal descendostomy was created. Postoperatively, the rectal stump became insufficient, and peritonitis and small bowel lesions developed at different locations.

Wound anamnesis

After proctectomy, the abdomen was closed with a suture which had to be reopened due to peritonitis and small bowel lesions. The initial antibiotic therapy consisted of a combination of Pipril/Combactam and ciprofloxacin; after an antibiotic sensitivity test, the therapy was switched to Meronem.

Aim of the treatment

The aim of the negative pressure wound therapy with Vivano® was an improvement of the wound situation with a granulating wound bed and a reduction of the laparostomy as well as optimal care of the enterocutaneous fistula in order to enable care to be provided at home.

Wound treatment

Prior to the first application of negative pressure wound therapy, the wound was debrided, while at the following dressing changes, the wound was only rinsed. In order to protect exposed intestinal wall and intestinal loops, the VivanoMed® Abdominal Kit was applied. The negative pressure system was combined with an adapter (Phametra), a ring-shaped, flexible elastomer that could be smoothly integrated into VivanoMed® Foam and connected to a stoma pouch. The adapter prevented an enlargement of the fistula, eventration of themucosa and release of aggressive faeces through the foam dressing. Hence, it protected the foam from being clogged and withdrawn from the wound and the wound from contamination and infection. A negative pressure of -50mmHg was applied during the entire therapy, and up to 100 mL of exudate were initially suctioned off.

Conclusion

The negative pressure wound therapy with Vivano® was combined with an adapter for fistulae in order to provide the optimal wound treatment in the case of a laparostomy with enterocutaneous fistula. The use of the fistula adapter decreased the time spent for wound treatment, increased the stability of the dressing und facilitated the mobilization of the patient. After 24 days, the wound bed was filled with granulation tissue and the wound stabilized. Subsequently, a conventional stoma system could be applied and stoma care could be performed without any problems. Meanwhile, the patient was mobile without assistance, and a surgical revision in order to remove the fistula was planned.

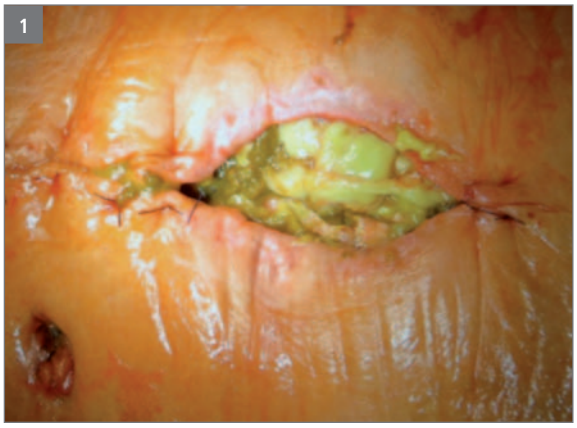

Day 0: The wound bed was covered with fibrin and small bowel conglomerate, and the wound edges were necrotic.

Day 0: Wound after debridement and prior to application of the foam dressing.

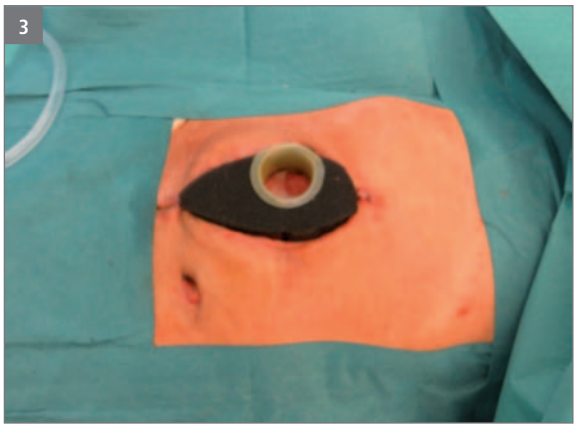

Day 0: The fistula adapter was applied to the small bowel fistula, and the foam was shaped around the cylindrical adapter.

Day 0: The foam was sealed with the film dressing at skin level.

Day 0: The adapter was fitted with a conventional stoma pouch.

Day 24: The wound bed was filled with granulation tissue and the wound edges were healthy. The negative pressure wound therapy was ended.

Treatment of tertiary peritonitis

S. Shlyapnikov, A. Demko, I. Batyrshin
Djanelidze Science Research Institute for Emergency Care, St. Petersburg, Russia

A 55-year-old man with multiple abdominal trauma.

Patient anamnesis

The patient had been beaten by an unknown assailant and was admitted to the emergency department. Diagnosis was polytrauma, including abdominal haemoperitoneum (2 L) and rupture of the ileal mesentery, ascending colon and caecum. The patient underwent right hemicolectomy, a 150 cm resection of the small intestine with ileotransverse anastomosis and drainage of the right pleural cavity.

Wound anamnesis

After 7 days, the patient's condition worsened dramatically, with low arterial pressure and clinical signs of diffuse peritonitis. On operation, leakage and rupture of the ileotransverse anastomosis was found. There was an open abscess into the peritoneal cavity and two perforated ulcers of the small intestine 30 and 50 cm from the Treitz ligament.

Aim of the treatment

Application of negative pressure wound therapy (NPWT) in the treatment of tertiary peritonitis.

Wound treatment

Resection and reconstruction of the anastomosis was performed together with suturing of the acute ulcers, abdominal debridement and application of NPWT. On day 11, the third day after NPWT initiation, the patient's condition was stabilising. However, intestinal contents were observed in the Vivano container, in connection with an acute ulcer of the anastomosis, requiring re-laparotomy. Resection anastomosis was performed, creating an end ileostomy, and NPWT was recommenced. After a further 6 days, the peritonitis had resolved and the abdominal wall was closed.

Conclusion

NPWT is an effective, useful and safe method for temporary abdominal-wall wound closure during re-laparotomy treatment of tertiary peritonitis.

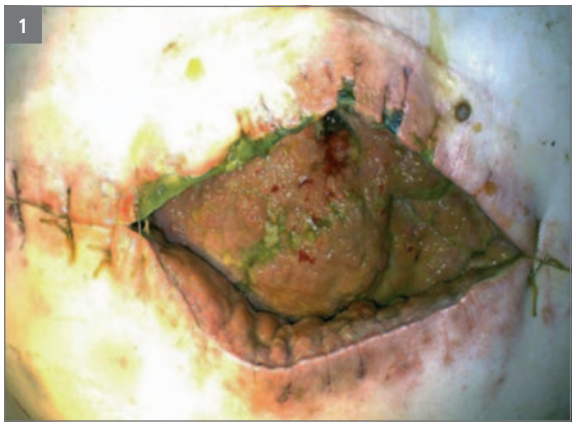

Day 7: Leakage from the ruptured ileotransverse anastomosis and an open abscess into the peritoneal cavity.

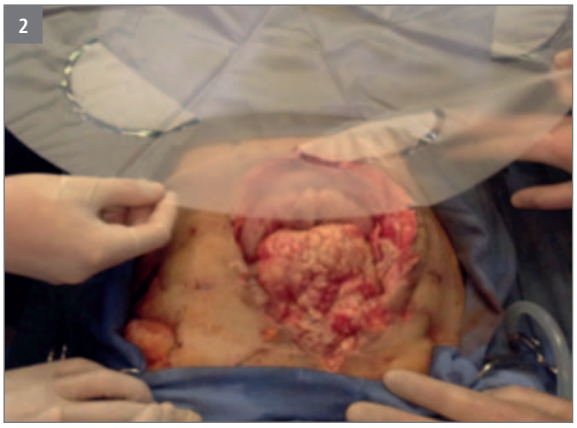

NPWT, step 1: Placement of the VivanoMed abdominal protection layer.

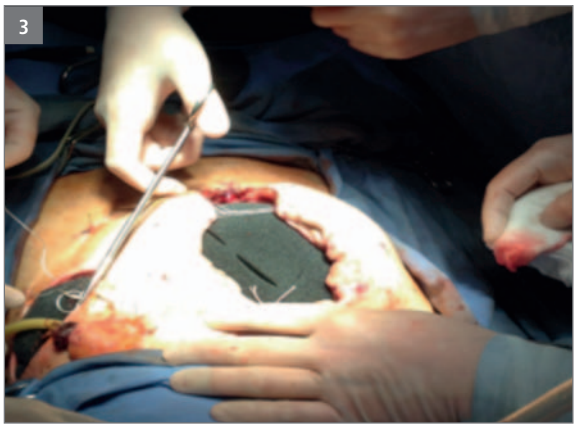

NPWT, step 2: Insertion of VivanoMed foam.

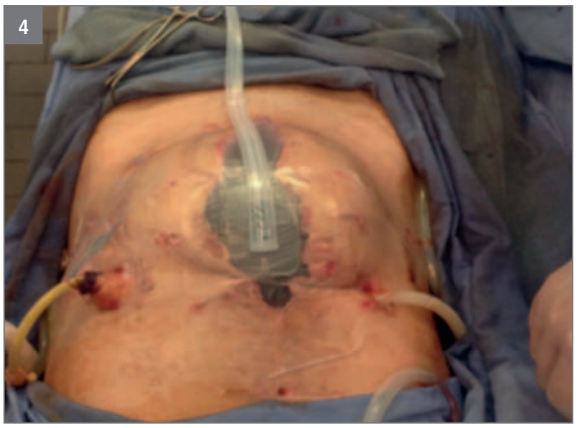

NPWT, step 3: The VivanoTec unit was connected to the VivanoMed Foam via the VivanoTec Port.

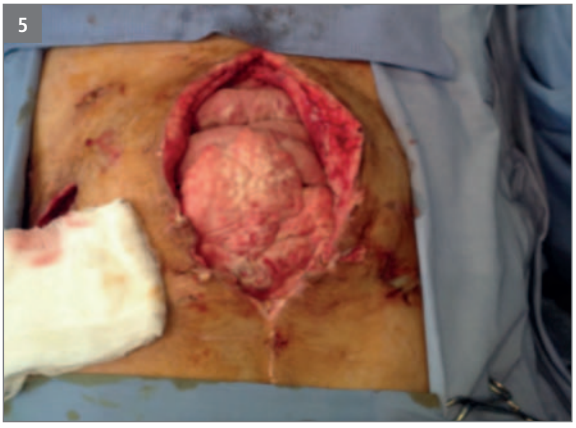

Day 17: Removal of the Vivano system. No peritonitis present. Abdominal wall could be closed.

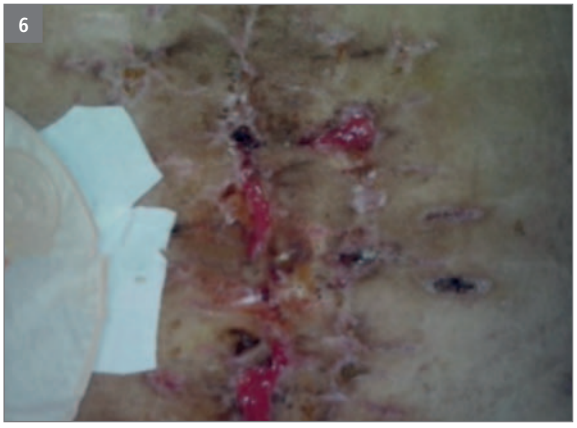

Healed defect: Prior to hospital discharge.

NPWT in the treatment of enteroatmospheric fistulas

R. Škuta, Y. Mykyta, I Keher
Clinic of General Surgery, Faculty Hospital of Trnava, Slovakia

A 42-year-old man with abdominal trauma after falling from a tree.

Patient anamnesis

A splenic rupture and haemoperitoneum were found. Within 9 days after splenectomy, the patient had developed lineal flexure perforation with left subphrenic abscess and peritonitis, and underwent partial resection of the colon transversum and colon descendens anastomosis. After 6 days, faeculent liquid was in the drain. Dehiscence of the anastomosis and peritonitis stercoralis were found. The patient was transferred to our hospital.

Wound anamnesis

Surgery on arrival revealed diffuse purulent peritonitis, multiple small-intestine adhesions, transversostomy necrosis and left subphrenic abscess. Abscess evacuation, right hemicolectomy, terminal ileostomy and drainage were performed, leaving an open abdomen. After 2 months and 14 operations with repeated necrectomy, plastic peritonitis remained after tracheostomy as well as a leak in the oesophago-gastric junction that was managed using endoscopic ligation. Despite repeated operations every 2–3 days, peritonitis remained, necrosis was found and enteric fistulas developed in the rigid and thickened small intestine.

Aim of the treatment

Application of negative pressure wound therapy (NPWT) as a part of the treatment of the open abdomen complication of enteroatmospheric fistula (EAF).

Wound treatment

NPWT was applied to treat septic complications, as special wound care therapy, and for discharge of intestinal contents. Individual Foley catheters were used to isolate the contents of the six fistulas present. After 12 NPWT applications, granulation had started and the wound was smaller. However, the intestinal fistulas remained. To reduce EAF secretion, a Foley catheter was inserted in the most proximal fistula and NPWT was applied for its isolation and active suction. The NPWT was temporarily halted during thrice-daily reduction of hypergranulation using boric acid. Reconstructive surgery was scheduled for 10 months as operation 106. Two parts of the small intestine with all six EAF were resected and two primary entero-enteral anastomoses were made. The open abdomen was closed using special polypropylene netting and the skin cover was reconstructed. After 3 months it had healed without any fistulas and no defect remained. Despite long-lasting paralysis due to inactivity, the small intestine started functioning again. The patient was discharged for home treatment with monthly visits to the ambulatory dispensary. The patient had full enteral intake without malnutrition, no abdominal wall defect or fistula and a permanent ileostomy.

Conclusion

Combining NPWT with moist healing, boric acid water and repeated operations together with long-term total parenteral nutrition led to successful healing despite many complications. Therefore, a multidisciplinary approach is essential and patience is necessary.

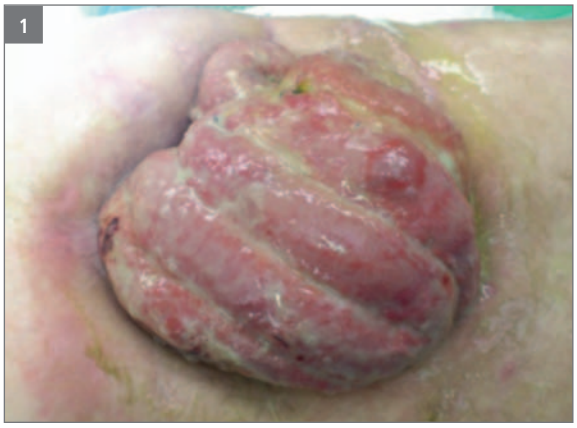

Pre-NPWT: Open abdomen with plastic peritonitis and an open fistula of the small intestine. A second fistula that was present opened later.

Day 1: Application of NPWT.

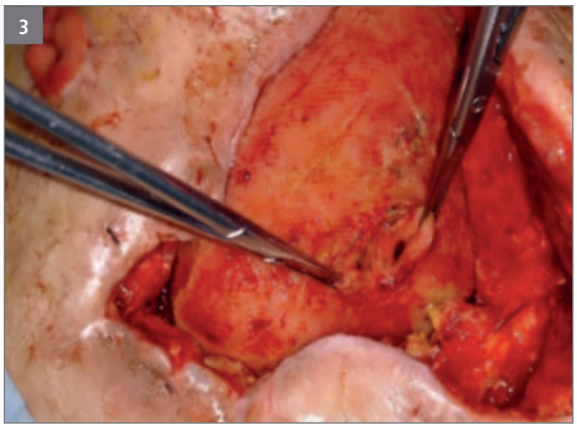

Following 12 applications: The wound is smaller and granulation has started. However, fistulas remain.

Prior to reconstructive surgery: Condition after 10 months of medical treatment. The six fistulas present in the small intestine were subsequently removed by resection.

Reconstructive surgery: The wound prior to skin cover reconstruction.

Patient discharge: Appearance of the wound at discharge.

Treatment of soft-tissue wounds

S.G. Shapovalov, A.S. Pleshkov, A.V. Panov
Nikiforov All-Russian Centre of Emergency and Radiation Medicine, Russian Emergency Ministry, St. Petersburg, Russia

Negative pressure wound therapy (NPWT) in the treatment of soft-tissue wounds of different origins and types. A representative patient from 15 cases treated with Vivano®.

Patient anamnesis

The mean patient (10 males, 5 females) age was 58.3±14.7 years. 7 patients had diabetes mellitus, 2 had obliterative atherosclerosis, 2 were paraplegic and 4 had no concomitant diseases.
A 69-year-old man with recurrent postoperative giant ventral hernia is presented here.

Wound anamnesis

The initial surgery had involved resection of an abdominal aortic aneurysm, complicated by dissection, and abdominal aortic replacement. After 17 months, plastic repair of a ventral hernia using a mesh graft was performed. 28 months later the patient had again developed hernia requiring surgical intervention.

Aim of the treatment

Application of NPWT to stimulate healing in soft-tissue wounds, also in combination with grafting and flap surgery.

Wound treatment

Repeated plastic repair using local tissue and prolene mesh was performed. NPWT was applied using Vivano® in 12 sessions of 2–4 days each over a total of 38 days. Sharp dermotension of the wound was performed and NPWT was reapplied. The wound healed and the patient was discharged for outpatient care 52 days after undergoing plastic surgery.

Conclusion

Positive results were obtained in 11 patients (73%), three cases (20%) improved but treatment was incomplete, and in one patient (7%) NPWT was considered ineffective. The mean treatment period was 40±44 days, with NPWT applied for a mean of 19±17 days during hospitalization.
Controlled NPWT is a safe and highly effective method in soft-tissue wound treatment, particularly in clinical cases where there are no effective alternative approaches.

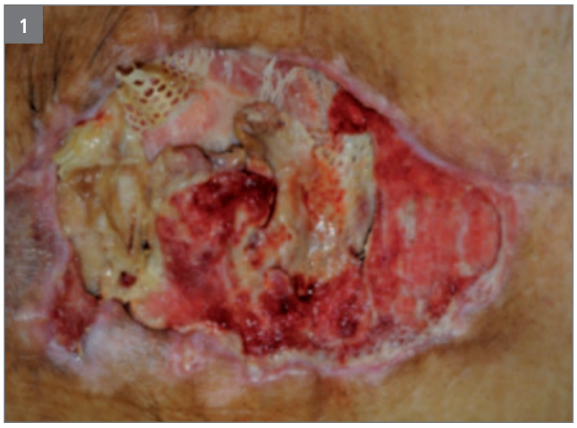

Day 6: After plastic repair of a giant ventral hernia using prolene mesh.

Day 6: Application of NPWT.

Day 38: The wound after application of NPWT.

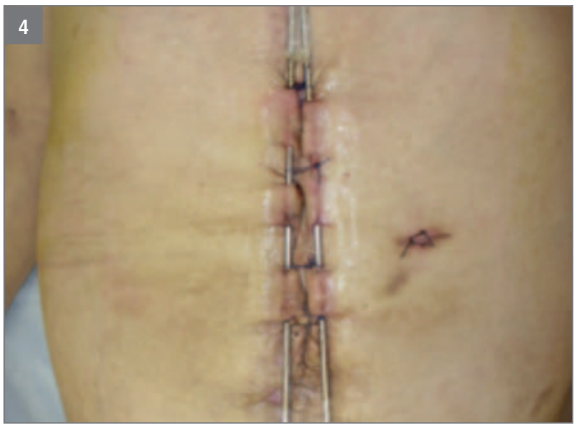

Wound closed: Sharp dermotension applied to the wound.

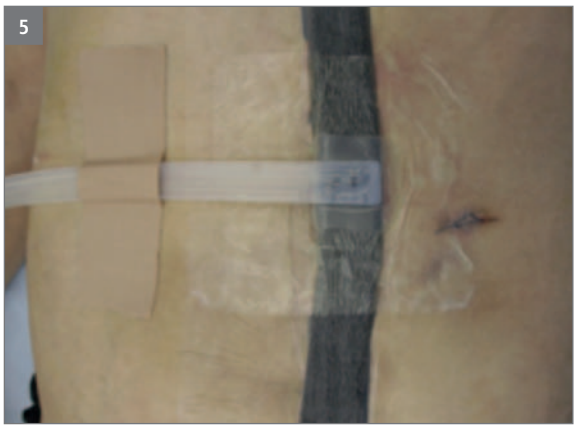

NPWT: Applied over the wound.

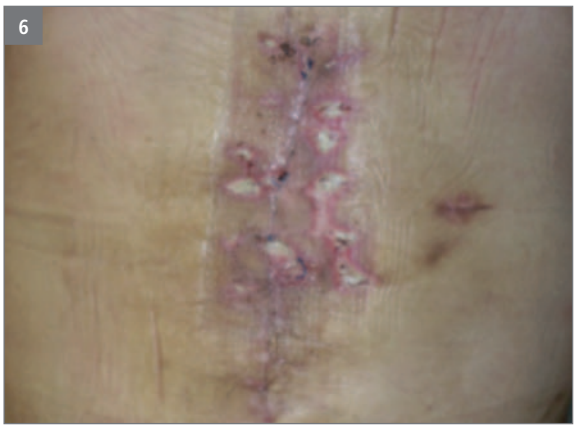

Healed wound: On day 52 after plastic surgery the patient could be discharged to outpatient care.

Vacuum-assisted laparotomy in the treatment of peritonitis and biliary fistula

V.N. Obolensky
Russian National Research Medical Hospital, Moscow, Russia

A 35-year-old patient with pancreatic necrosis, peritonitis and biliary discharge.

Patient anamnesis

The patient had undergone emergency abdominal surgery for a bleeding ulcer. Laparoscopy revealed a duodenal ulcer penetrating the pancreas with bleeding from the head glands and vessels, and an inflammatory infiltrate involving the hepatoduodenal ligament, common bile duct and gallbladder. Twothirds of the stomach was resected using the Hofmeister-Finsterer operation, with duodenal stump closure and cholecystectomy.

Wound anamnesis

After 5 days, remedial re-laparostomy was performed because of marked peritonitis symptoms. Necrosis of the pancreatic head and enzyme peritonitis were found. After 4 days, remedial re-laparostomy was once more performed, which revealed positive dynamics. Within 6 days, marked biliary discharge from the sutures of the lower corner of the wound occurred. Re-laparostomy was repeated. Ongoing peritonitis was diagnosed with bile on postoperative adhesions and bile leakage from the cystic duct stump.

Aim of the treatment

Application of negative pressure wound therapy (NPWT) with Vivano® in laparostomy in connection with a complicated wound with various origins.

Wound treatment

The abdominal cavity was cleansed, the cystic duct stump was fixated using TachoComb® sponge, and a vacuum-assisted dressing was applied in the peritoneal cavity using a disposable sterile Vivano®Med abdominal kit that was attached to the Vivano®Tec unit for applying negative pressure. On the next day, the patient was transferred from the intensive care unit to the surgical ward, and on the following day, an abdominal compression bandage was applied over the vacuum-assisted dressings to allow the patient to be mobilized. The vacuum-assisted dressing was removed 2 days later. No indication of peritonitis was found, drainage was installed in the cystic duct stump area and the abdominal wall wound was sutured. Within 2 weeks, the laboratory parameters were normal and the bile leakage had ceased. The drainage and stitches were removed and the patient was discharged. There were no signs of recurrence or wound complications at the 11-month follow-up.

Conclusion

NPWT can be applied in laparostomy in connection with the treatment of complicated abdominal wounds with multiple origins.

Day 1: Wound appearance at baseline.

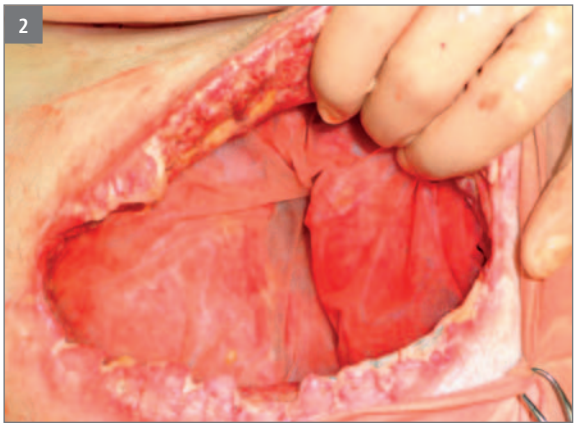

Day 1: Dressing applied to peritoneal cavity after abdominal cavity cleansing.

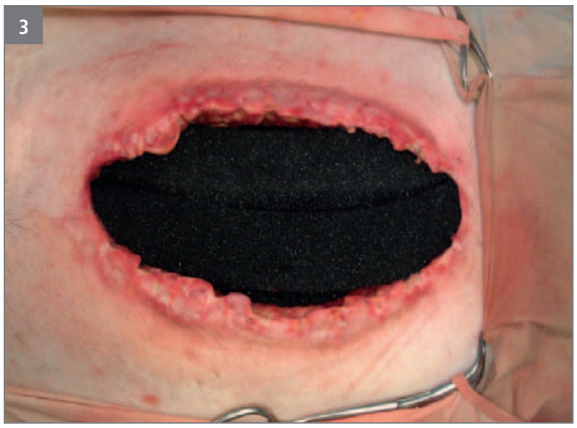

Day 1: Insertion of foam layer.

Day 1: Application of dressing and Vivano.

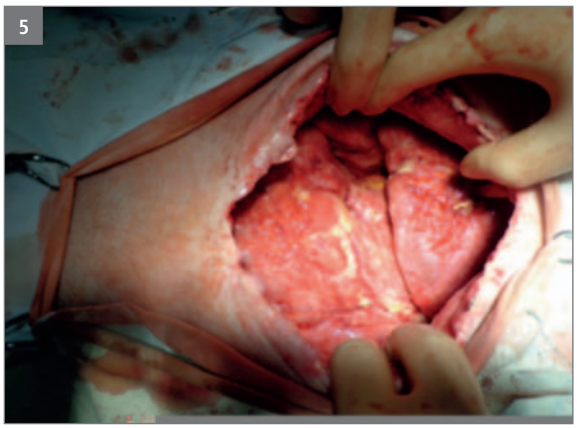

Day 4: Removal of vacuum dressing. No infection or peritonitis present.

Day 7: Appearance of the sutured abdominal wall.

Does NPWT reduce wound infection?

Lenka Veverkova, Michal Reska, Jan Zak, Ivan Capov
Masaryk University, Brno, Czech Republic

Approximately two million patients in the EU alone suffer nosocomial or hospital-acquired infections every year, of which more than 50% are drug-resistant, with methicillin-resistant Staphylococcus aureus (MRSA) constituting the most frequent cause worldwide. As the causal relationship between microorganisms and wound healing progression remains unclear and it is known that it is unnecessary to eliminate all microbial organisms, the question remains open as to whether NPWT should be used in infected wounds.

Aim of the study

A prospective study to determine whether NPWT reduces infection.

Patients

A total of 70 patients with infected defects were treated using negative pressure wound therapy (NPWT) between January 2010 and December 2013. Patients had a median age of 62 years (23–85) and were hospitalised for a median of 39 days (10–113) due to the abdomen, chest, limb or sacral region.

Wounds

The wounds varied in size from 8 cm × 5 cm to 38 cm × 35 cm and were infected.

Wound treatment

The patients received NPWT for a median of 14 days (5–45). Material was obtained from the wound using a swab before, during and after NPWT for cultivation to determine the level and profile of bacteria present.

Results

All wounds healed without any mortality, accompanied by a decrease in the number of cultivations finding, although Staphylococcus aureus and Escherichia coli remained present during and after NPWT treatment.
Interestingly, NPWT treatment was age-dependent, with patients aged 60 or older years receiving NPWT for significantly longer periods than patients aged under 60 (median 18 days [4–45] and 11 days [4–34] respectively; $p = 0.034$), with more frequent dressing changes (median 4 days and 3 days respectively), and re-mained significantly longer hospital stays (median 49 days [15–114] and 29 days [7–100] respectively; $p = 0.003$).

Conclusion

The positive cultivation results do not necessarily mean that NPWT leads to a clinical manifestation. Therefore, this prospective study is unable to provide a clear yes or no answer as to whether NPWT diminishes wound infection. In this study, wound bacterial load decreased during treatment in more than a fifth of the cases and all wounds healed with no mortality. Thus, NPWT can be recommended for treatment of infected exuding wounds.
For further information see L. Veverková et al. Outcome of negative pressure wound therapy with different devices. Wound Medicine 6 (2014) 15–17.

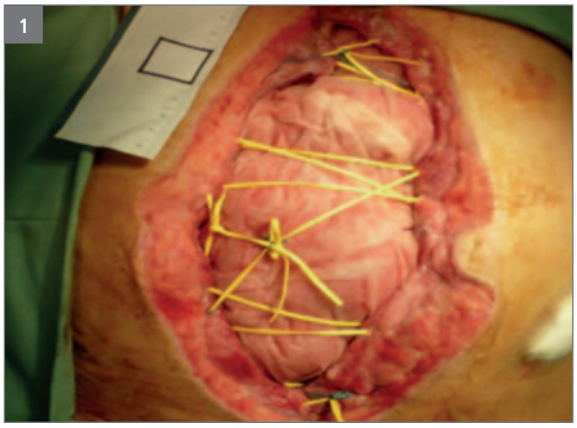

Abdominal wound: Showing laparostoma with contamination.

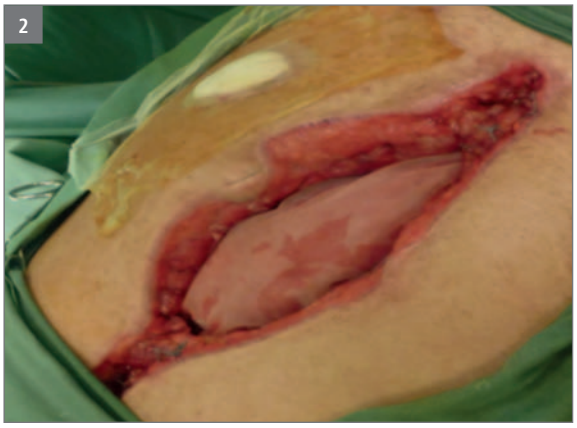

Day 14: After NPWT treatment the wound was clean.

Resuture: The clean wound could be resutured.

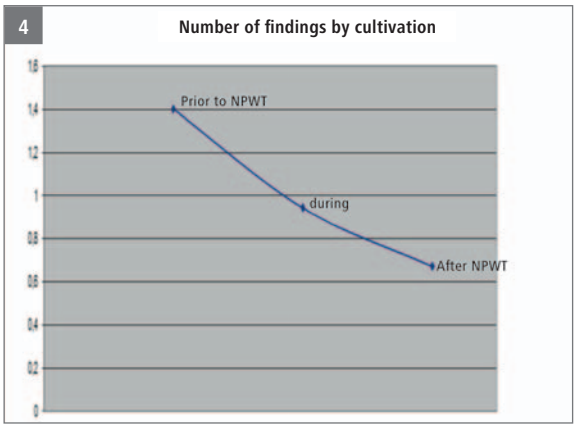

Bacterial load: Number of cultivations finding at different stages of treatment.

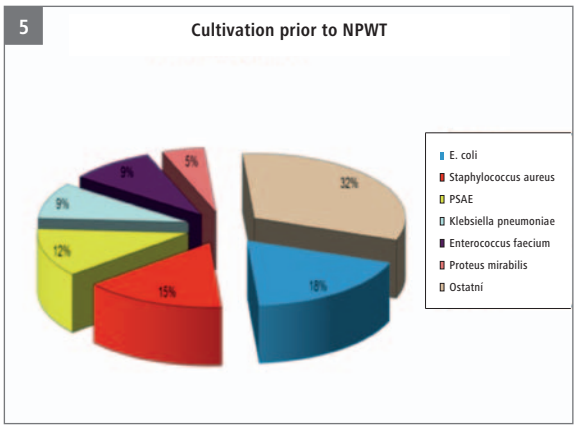

Bacterial profile: Prior to NPWT.

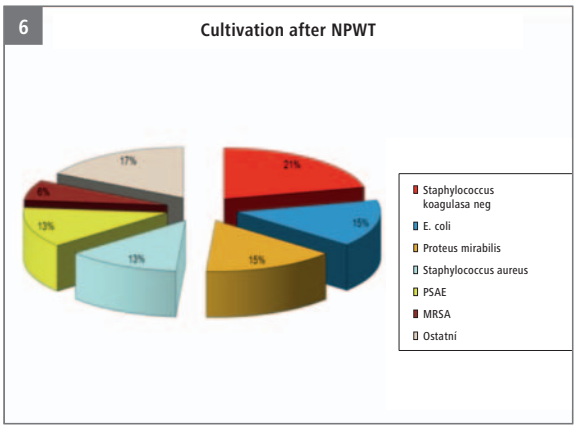

Bacterial profile: On completion of NPWT treatment.

High-energy soft-tissue injuries

Mazen Ali, Orléans, France

Three men aged 54 (Patient 1), 48 (Patient 2) and 78 years (Patient 3), with high-energy soft-tissue injuries.

Patient anamnesis

Patient 1 had sustained a high-velocity trauma to the left leg with a significant defect of the posterior thigh in connection with a car accident. Patient 2 had a haematoma with abscess of the medial surface of the right leg after a violent trauma. Patient 3 had suffered a large crush wound to the back of the left leg.

Wound anamnesis

The wound in Patient 1 was associated with nerve injury and contamination. Following rinsing and debridement, the skin flap was sutured. Skin necrosis and infection was found after the second dressing change on day 6. In patient 2, skin necrosis and infection was present on day 3. Patient 3 had suffered massive tissue damage and loss, with wound contamination. The wound was rinsed and debrided, and the skin flap was sutured. By day 6, cutaneous and muscular necrosis had developed.

Aim of the treatment

Application of negative pressure wound therapy (NPWT) with Vivano® to manage high-energy soft-tissue injuries; elimination of infection and support of granulation formation to accelerate healing.

Wound treatment

Dressing changes were performed every 3 days on average accompanied by antibiotic treatment of approximately 6 weeks as standard.
Following extensive debridement in Patient 1, NPWT was applied at –75 mmHg, with extra skin protection provided by a thin hydrocolloid dressing around the edges. After 3 days, the tendon was exposed and infection remained. By day 6, rapid granulation had developed that covered the tendon, and there was no more infection. The patient was discharged to continue treatment at home. Wound healing was complete by day 30 without grafting and with a full range of movement of the knee. The patient returned to work and normal daily activities after 45 days. Patient 2, after drainage and debridement, exhibited a skin defect with bone exposure. NPWT was initiated at –125 mmHg, the defect being covered with a silicone interface layer beneath the foam. The patient was discharged after 3 days to continue treatment at home. By day 6, rapid granulation had developed that covered the bone and the patient returned to work. The wound had healed completely by day 30. Patient 3 underwent NPWT following debridement. Rapid granulation developed, enabling skin grafting. Complete wound healing was observed by day 45 and the patient returned to normal activities.

Conclusion

All three patients healed, with a mean treatment time of 16 days (4–35) and without any complications during or after NPWT using the Vivano®. Wound swelling was reduced, serous fluid drainage promoted, bacterial load reduced and granulation tissue formation stimulated. Adequate debridement is necessary prior to NPWT in order to optimise the clinical outcome. The Vivano® system has become a vital tool in the management of high-energy soft-tissue injuries, reducing the wound closure time and hospital stay while improving the patient's quality of life.

Patient 1, day 0 of NPWT: Skin necrosis and infection 6 days after initial injury debridement and flap suture. After extensive debridement, NPWT was commenced.

Patient 1, day 30: Complete wound healing without the need for a skin graft.

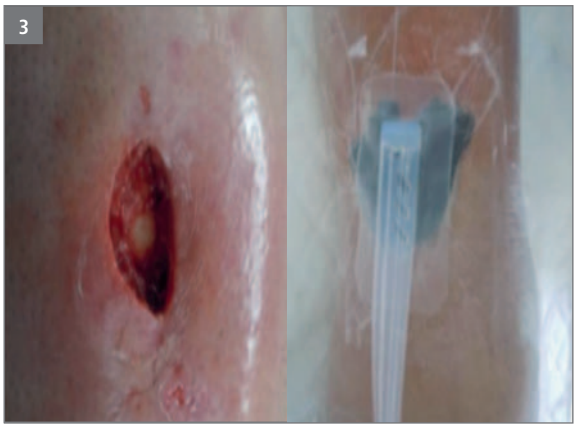

Patient 2, day 0 of NPWT: The necrotic and infected tissue that had developed 3 days after admission underwent drainage and debridement, producing a skin defect with exposed bone that received NPWT at –125 mmHg, and was covered with a silicone layer.

Patient 2, day 30: Complete wound healing.

Patient 3, day 0 of NPWT: Cutaneous and muscular necrosis 6 days after initial injury debridement and flap suture. After extensive debridement, NPWT was started.

Patient 3, day 45: Complete healing following NPWT and subsequent skin graft.

NPWT in sacral wounds

Piotr W. Trzeciak, Joanna Porzezynska, Dominik A. Walczak, Karolina Ptasinska,
Wojciech Falek, Leokadia Kozaczek
John Paul II Memorial Hospital, Belchatow, Poland

Two men, aged 62 (Patient 1) and 78 years (Patient 2), with wound dehiscence and pressure ulcer in the sacral region.

Patient anamnesis

Patient 1 had a wound dehiscence. This constitutes a gateway for infection, while escalated serous liquid secretion can lead to secondary skin infections or bedsores. The patient had hypertension and a body mass index (BMI) of 33 kg/m^2. Patient 2 had a pressure ulcer. Underlying diseases included hypertension, diabetes mellitus and arteriosclerosis, with a BMI of 37 kg/m^2, and the patient had previously suffered two strokes, which had required rehabilitation for fine motor skills.

Wound anamnesis

Patient 1 had received primary treatment for rectal cancer with a low anterior resection without any complications and had been discharged. Ten days after surgery, straw-coloured liquid started to flow from the wound, with wound dehiscence after 18 days. The complication of aspiration of gastric contents during the induction of general anaesthesia had occurred. A second wound dehiscence occurred 12 hours later. Following reoperation, the patient suffered respiratory insufficiency, requiring 30 days intensive care, and developed fascial necrosis. Primary wound treatment was administered with moist gauze and topical octenidine. The wound developed into a large evisceration (16 cm × 20 cm).
The pressure ulcer of Patient 2 was fibrinous and developed necrosis. Medication included ciprofloxacin.

Aim of the treatment

Application of negative pressure wound therapy (NPWT) with Vivano® in the treatment of complicated sacral wounds.

Wound treatment

The infected wound of Patient 1 was treated using ertapenem and anticoagulants, and NPWT was initiated and applied continuously for 21 days at –125 mmHg. A hernia support was used. Subsequently, adaptive surgery was performed, with mesh implantation. The patient was discharged 14 days later.
The infected wound of Patient 2 was treated using ciprofloxacin, and NPWT was applied as in the case of Patient 1. During NPWT, the patient developed an anal fistula, in response to which a stoma was created on the sigmoid colon. On completion of NPWT, the patient had no infection or pain and was discharged with a follow-up after 2 months.

Conclusion

NPWT is useful in the conservative management of wound dehiscence, particularly in patients with a severe condition, enabling better preparation of infected wounds for subsequent surgical treatment than conventional dressing. Similarly, NPWT can be applied to treat complex wounds in the anorectal region. In both situations, NPWT will shorten the duration of hospitalisation and reduce treatment costs.

Patient 1: Necrotic pressure ulcer with fibrinous wound bed.

Wound preparation: For application of NPWT.

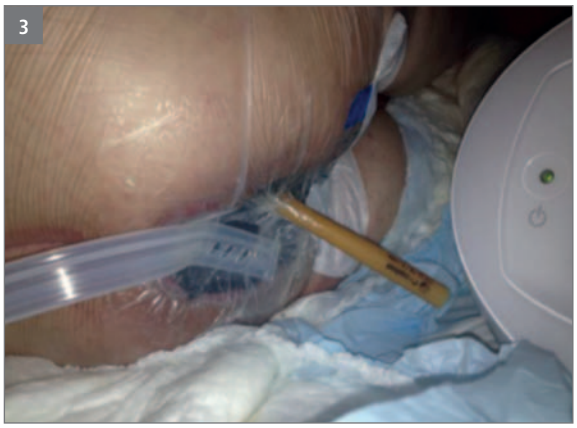

NPWT application: A continuous negative pressure of –125 mmHg was applied using the Vivano, with an Atrauman Ag contact layer.

Development of anal fistula: Treated by creation of a stoma on the sigmoid colon.

NPWT, day 12: Wound status after sixth wound dressing change.

Completion of NPWT: No infection or pain. Patient was discharged from hospital.

Purulent necrotic lesions in patients with peripheral arterial disease

V.V. Zavatsky
Djanelidze St. Petersburg Research Institute of Emergency Medicine, St. Petersburg, Russia

Two 73-year-old men with purulent necrotic lesions and peripheral arterial disease.

Patient anamnesis

Patient 1 had a trophic ulcer in the lower third of the right leg in the vena saphena magna drainage area after aortocoronary bypass. A reverse femoro-popliteal bypass graft was performed. Within a month, ulcers developed on the medial surface of the lower third of the leg. Patient 2 suffered from type 2 diabetes mellitus and developed a neuroischemic form of diabetic foot syndrome in connection with arterial occlusion in the lower leg.

Wound anamnesis

The trophic ulcers of Patient 1 became larger and more necrotic, compounded by pains in the foot and shin. Sulodexide was ineffective. The necrotic circular trophic ulcer in the lower and mid-third of the leg became purulent with perifocal inflammation. A trophic ulcer developed in the calcaneal region. Patient 2 presented with a trophic ulcer in the calcaneal region of the right foot. Ointment and ulcer excision with phlegmon surgery were unsuccessful. The ulcer increased in size, accompanied by foot oedema and hyperaemia, becoming necrotic at the wound edges and purulent. The patient was admitted with wounds on the plantar and lateral surfaces.

Aim of the treatment

To treat non-responsive purulent necrotic lesions with negative pressure wound therapy (NPWT) using Vivano®.

Wound treatment

In Patient 1, systemic treatment included antibacterial, anti-inflammatory and disaggregant therapies together with substitution transfusion. Local treatment consisted of povidone dressings with iodine and vacuum therapy. Subintimal recanalization of the superficial femoral artery and posterior tibial artery (PTA) with reentry of the anterior tibial artery was performed. After 4 days, hydrosurgical ulcer debridement was performed. NPWT was initiated 2 days later, in continuous mode at –125 mmHg for 14 days, with a total of six dressing changes, dressing changes being performed every 2–3 days. On day 7 after the initial debridement, the trophic ulcer in the calcaneal region was debrided and NPWT also applied there, connecting the two wound beds. The main defect on completion of NPWT was closed using a perforated transplant. Autodermoplastic reconstruction of the calcaneal region was performed and NPWT halted after 6 days. However, the wound deteriorated and NPWT was reapplied after another 6 days for a further 17 days, when autodermoplastic reconstruction was repeated. 99% skin acceptance was observed without any local inflammation 16 days after plastic surgery, and complete epithelialisation was observed after 2 months. Patient 2 received the same systemic treatment, but without transfusion, and anti-secretory therapy. Local treatment was the same, with the addition of Prontosan® wound irrigation solution. To rectify PTA occlusion, balloon angioplasty was performed accompanied by PTA revascularisation and plantar arch reconstitution. Hydrosurgical debridement was performed 5 days later, followed after 2 days by NPWT initiation in continuous mode with a negative pressure of –125 to –120 mmHg, with 14 dressing changes, changes being performed every 2–3 days. After 20 days of NPWT, the skin flap was fixed with foam. On day 38, sub-total calcanectomy was performed together with plastic surgery using local tissues and autodermoplastic reconstruction was performed with perforated transplant. The patient was discharged with healed wounds 65 days after hospitalisation.

Conclusion

NPWT with Vivano® can be used to treat non-responsive, purulent necrotic lesions.

Patient 1: Purulent and necrotic circular trophic ulcer.

Wound preparation: Hydrosurgical debridement.

NPWT application: A continuous negative pressure of –125 mmHg was applied using Vivano.

NPWT, day 3: First dressing change. Secretion of 100 mL/day.

NPWT, day 14 (end): Sufficient granulation for defect closure using a perforated transplant.

Healed wound: Complete epithelialisation observed 2 months after plastic surgery.

Chronic wounds in diabetic foot syndrome

Csaba Toth
Kenezy Hospital, Debrecen, Hungary

Three diabetic patients with foot ulceration, two of whom required amputation.

Patient anamnesis

Patient 1 was a 47-year-old man with type I diabetes compounded by obesity and hypertension, who was taking aspirin and statin. Patient 2 was a 62-year-old woman who had previously undergone a left femoral amputation because angiography had revealed poor outflow and the ulcer had become gangrenous. Patient 3 was a 31-year-old woman with type II diabetes compounded by obesity, hypertension and smoking.

Wound anamnesis

Patient 1 had a large necrotic wound (15 cm × 8 cm) with pus on the left foot and a second large wound on the plantar side. Treatment consisted of extensive necrectomy of the skin, subcutaneous tissue and tendons, and the patient received amoxicillin and clavulanic acid, with metronidazole administered intravenously and moxifloxacin administered later on following culture. Patient 2 had been readmitted with chronic fasciitis 2 months after amputation. Patient 3 had a chronic crural ulcer on the left, which after 2 years of treatment by dermatologists had been treated with crossectomy, varicectomy and stripping, but still failed to heal after 2 months.

Aim of the treatment

To stimulate healing in chronic diabetic foot wounds using negative pressure wound therapy (NPWT) applied by means of Vivano®.

Wound treatment

After debridement of subcutaneous tissue and the tendons in Patient 1, it proved impossible to save the foot, and the foot was removed by transmetatarsal amputation. Culture showed infection with several bacterial species. Following debridement, the first NPWT using Vivano® was applied in continuous mode at –125 mmHg with Atrauman® Ag dressing. The first dressing change was on day 4. A free skin transplant was performed on day 8. NPWT was applied intermittently at –80 mmHg for a further 5 days over a silicone layer.
The wound of Patient 2 underwent necrectomy and debridement followed by osteotomy prior to the first application of NWPT with a continuous negative pressure of –125 mmHg. The foam was changed after 4 days, followed by a second NPWT application. Secondary suture closure of the wound was performed on day 8.
The ulcer of Patient 3 underwent similar treatment starting with NPWT for 4 days as in the case of Patient 2, with Atrauman® Ag dressing between the foam and the wound. A free skin graft was performed on day 5 followed by NPWT for 4 days under the same conditions as in the case of Patient 1.

Conclusion

All three patients exhibited healing of chronic wounds after NPWT using Vivano®, which stimulated the skin graft uptake when applied.

Patient 1: Large necrotic wound with pus.

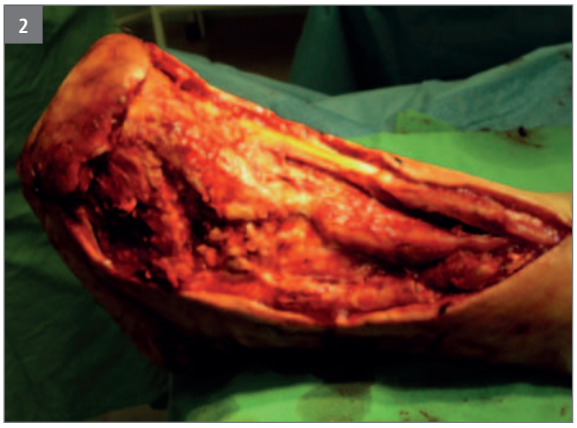

Day 0: Foot amputation and debridement in preparation for NPWT.

Day 0 of NPWT: Application of continuous negative pressure at –125 mmHg using Vivano, with Atrauman Ag dressing.

Day 4 of NPWT: Prior to application of new foam and continued NPWT.

Day 8 of NPWT: Free skin transplant.

Day 30: NPWT was continued intermittently with a negative pressure of –80 mmHg up to day 13. The skin transplant covers the wound.

Treatment of a complex leg defect following electrical burn injury

Alexandru Ulici, Iulia Tevanov, Madalina Carp, Gabriel A. Sterian, Catalin Nahoi
Paediatric Orthopaedics, Romania

A 17-year-old male with high-voltage burns was treated for a major chronic soft-tissue defect of the right leg.

Patient anamnesis

The patient had suffered third- and fourth-degree burns to 60% of the body surface. Necrotic muscles and tendons of the right lower leg had been excised and extensive plastic surgery performed in another department.

Wound anamnesis

On transfer to the department, the patient exhibited two soft-tissue defects of the right leg: a major defect with tibial bone exposure measuring 15 cm × 3 cm in the lower half, and a smaller defect measuring 7 cm × 2.5 cm which exposed the peroneal malleolus.

Aim of the treatment

Application of negative pressure wound therapy (NPWT) with Vivano® to treat a complex burn wound.

Wound treatment

The devitalised, exposed tibia was resected and the wound edges excised. The wound was cleaned and covered with nanocrystalline silver wound dressing to control local infection, and a hydrocolloid dressing was used to protect the skin between the defects and that of the wound edges. A foam bridge linked both defects to allow the use of a single vacuum port. Initial NPWT application was in continuous mode. However, the patient lost approximately 600 mL blood within the first 12 hours due to poor bone haemostasis. Vivano® was changed to intermittent mode and haemorrhage ceased within 24 hours. Intermittent suction was used throughout the therapy. Local cleaning, soft-tissue avivement and dressing changes under general anaesthesia were performed twice weekly for 6 weeks. Silver wound dressings, and intermittently silicone wound dressings, were used to control local infection, and the patient received intravenous antibiotics (colistin and gentamycin). On day 10 of NPWT, local extension of the granulation tissue was observed and a silicone-based dressing was applied to the wound site to stimulate granulation tissue formation and NPWT was continued with –115 mmHg for 2 minutes and –50 mmHg for 4 minutes. During the final stage of NPWT, the bone surface of the main defect remained exposed over an area measuring approximately 1 cm × 0.5 cm in the mid-region. This was covered using silicone dressing to encourage granulation, and silver dressing was applied to the already granulated area to eradicate **Pseudomonas aeruginosa** infection. On completion of NPWT, skin grafting was performed on both receptor beds using a free skin graft from the ipsilateral thigh, and moist dressing was applied. The patient recovered acceptable standing and walking functions of the leg.

Conclusion

After extensive plastic surgery, two large soft-tissue defects remained which were successfully covered using NPWT. Major amputation could thus be avoided.

Patient transfer: Following major plastic surgery, two defects with exposed bone remained bone. Here, the main defect is shown.

Wound preparation: Resection of the devitalised, exposed tibia and wound-edge excision prior to NPWT.

NPWT, day 15: The smaller lateral defect was almost completely covered with granulation tissue.

NPWT, final stage: Incomplete granulation over the bone of the major defect.

Induction of full granulation: Silicone dressing applied to the remaining uncovered area to facilitate granulation so that skin grafting can be performed. Silver dressing placed over the granulation tissue already formed in order to eradicate bacterial infection.

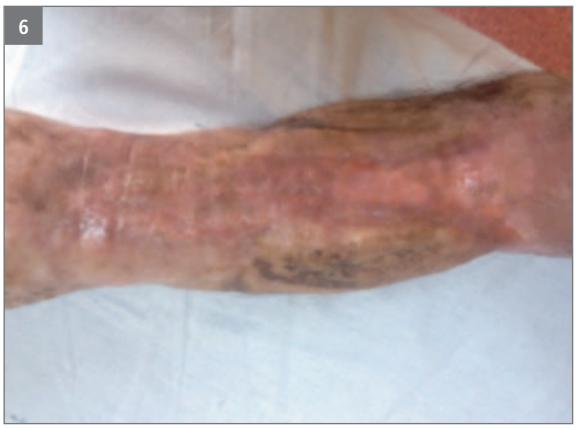

Healed defect: The entire skin graft site regained full skin integrity 3 months after grafting.

helps healing.

PAUL HARTMANN AG
Paul-Hartmann-Straße 12
89522 Heidenheim
Germany

Visit our website:
www.vivanosystem.info

(10/14)